BENIGN UTERINE NEOPLASMS.

Fibroid Polypi.

Cervical.—These are always more or less pedunculated, generally with slender stems. True fibroid polypi arising from the cervix are not common. More generally is it the case that cervical polypi are of glandular origin.

As in the illustration, the gross appearances of the growths where they contain much fibrous tissue, strongly resemble malig-

Fig. 232.

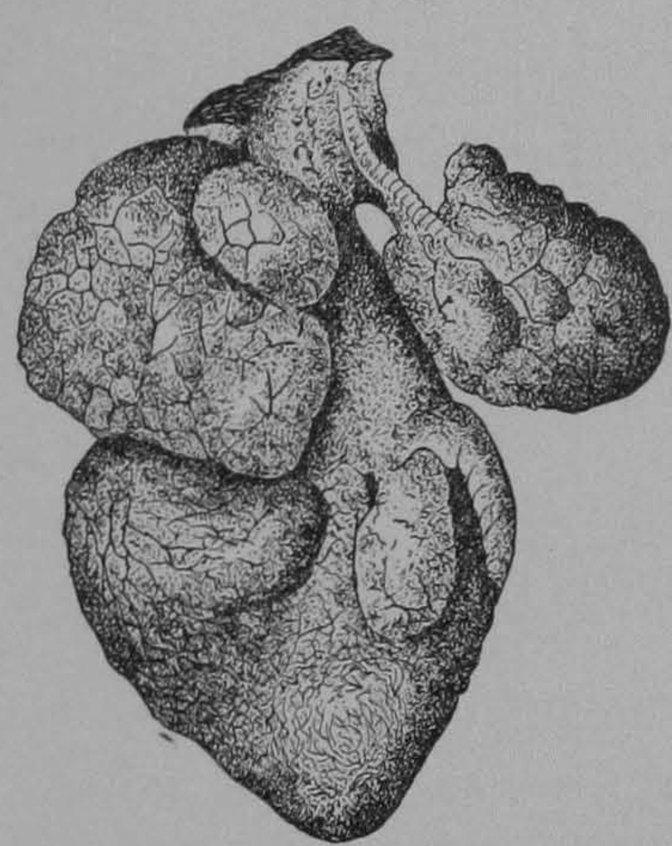

Small Muriform Polyp of the Cervix (papillary fibroma with glandular hypertrophy).

nant disease, and the diagnosis may rest entirely on the microscopic appearances.

Cervical polypi, being exposed to the vaginal filth, usually produce a nasty, purulent discharge, profuse and ill-smelling. There is always more or less general glandular endocervicitis with them, the cervix being as a rule widely gaping and eroded. They do not reach a large size. If the pedicle be long and the mass hang entirely outside the cervix, strangulation may occur in the growth and a spontaneous cure ensue.

Uterine.—These are merely transitional between the mucous polypi already described and submucous fibroids. They are de-

scribed by many authors as the result of the uterine contractions forcing the submucous fibroids into a pedunculated form—an attempt at spontaneous cure. The uterus being in a condition

FIG. 233.

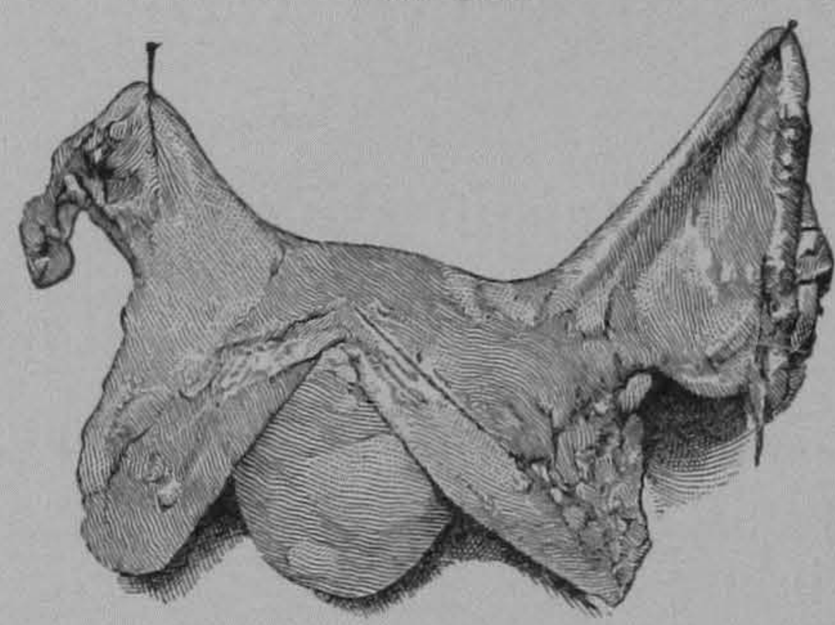

Intra-uterine Fibroid Polyp.

of chronic metritis is always more or less enlarged, and its cavity is distended. Purulent endometritis is a common accompaniment, and general glandular hypertrophy is usually present.

Some of these polypi have short stems, but their pedicles may be so long as to cause the bulb of the polypus to hang from the vulva. Unlike the glandular variety, fibroid polypi are usually single.

SYMPTOMS.—These are very similar to those occasioned by small, submucous fibroids. There are pronounced uterine cramps, purulent discharge, increased menstruation, hemorrhage, backache, and a sense of weight in the pelvis, as common symptoms. The discharge is profuse generally, and the bleeding is marked. There may be a continuous oozing all the time, or the bleeding may occur as hemorrhages, very profuse and alarming. The cervix uteri is generally patulous. Fibroid polypi are not easily mistaken for other growths when once seen and felt.

TREATMENT.—Fibroid polypi are not amenable to medical treatment. Pedunculated fibroid polypi from the cervix may readily be removed by torsion. Should the base be firm or broad, it may be severed with the scalpel and a few sutures taken to correct the hemorrhage and approximate the cut surfaces.

Small polypi from the body of the uterus may also be removed by torsion, but it is better to combine with this curettage and gauze packing if the general endometrium be, as it usually is, much hypertrophied.

Large polypi are occasionally quite formidable affairs. In case the finger cannot be introduced into the vagina at all, owing to the

size of the growth, it is proper to cut away enough tumor to enable the passage of the finger and stout forceps. The pedicle is sought for and secured by forceps, when the growth is to be cut away. The pedicle may be twisted or sutured. As these growths are unclean, irrigation and gauze dressings are indicated. It must not be forgotten that in old women malignant disease is apt to supervene upon any long-standing inflammatory condition of the inside of the uterus. Therefore it is always well to submit the curettings and the polypus to the microscopist for examination.

Uterine Fibroids.

Pathology.—Uterine fibroids are composed of an increased growth in the fibrous and muscular structures of the organ; they

Fig. 234.



Uterine Fibro-myoma, microscopic view.

are generally, then, fibro-myomata. They are non-malignant tumors, but not infrequently is malignant disease associated with existing fibroid. They may occur just beneath the uterine mucous membrane, or deeper in its walls, or immediately under the peritoneum. They are then known as submucous, interstitial, or subserous. They are prone to occur in nests or groups, and the several varieties are very often associated; precise classification in such a case is not possible. In gross appearances these tumors are of a deep red color or pale. They are firm, and under the knife cut like gristle when the fibrous tissue predominates, but are less firm when the muscular fibres are in excess. Upon section the striations of bundles of fibre may be seen, and nests of fibrous tissue bulge from the cut surfaces as nodules. Their walls may

myxoma = a mucous tumor.

contain cysts filled with clear, bloody, or purulent fluid. They are prone to undergo various degenerative processes—cystic, myxo-

FIG. 235.

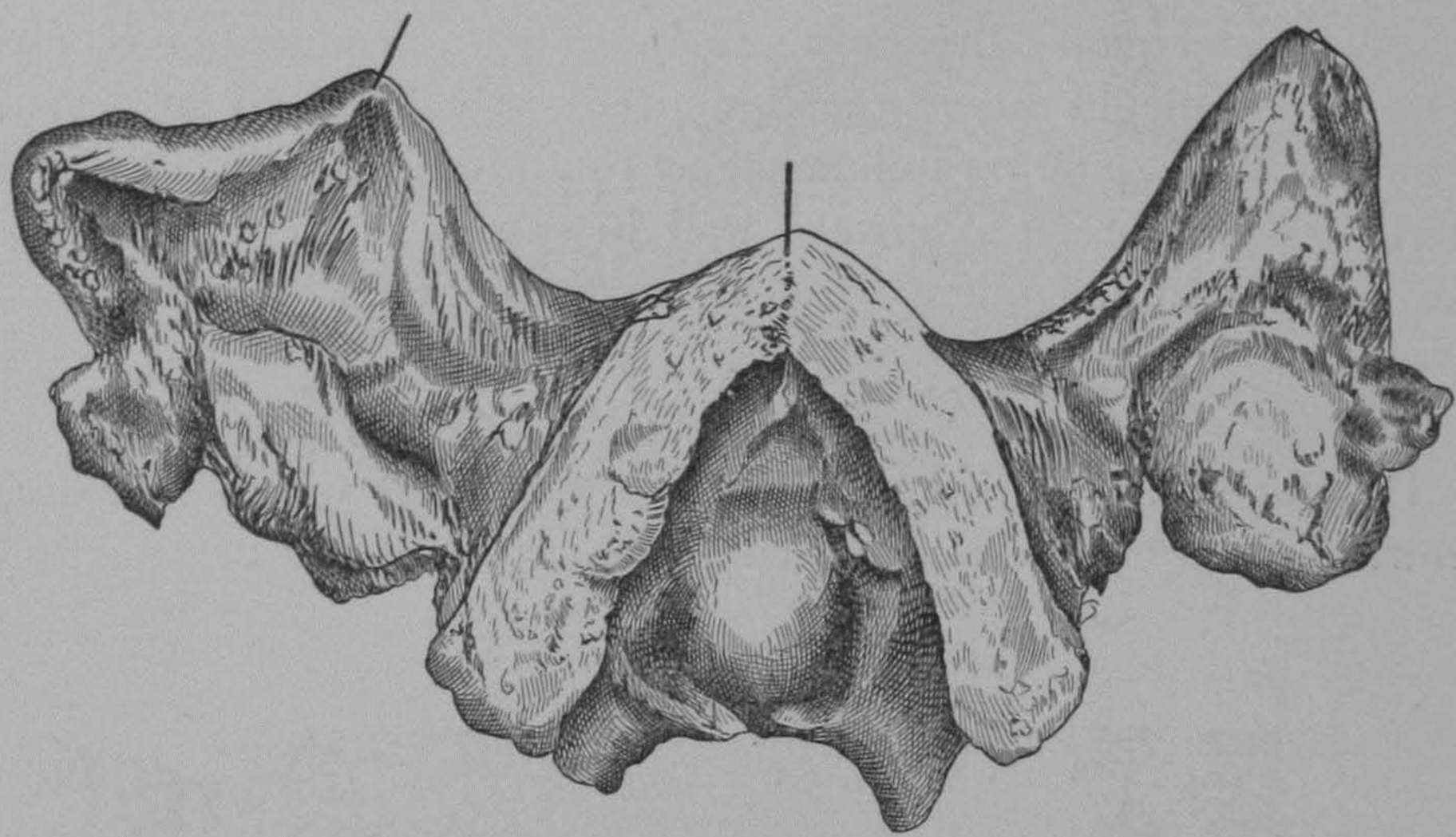

Submucous Uterine Fibroma.

matous, fatty, and even calcareous degeneration. There are two forms of cystic degeneration—one due to myxomatous changes;

FIG. 236.

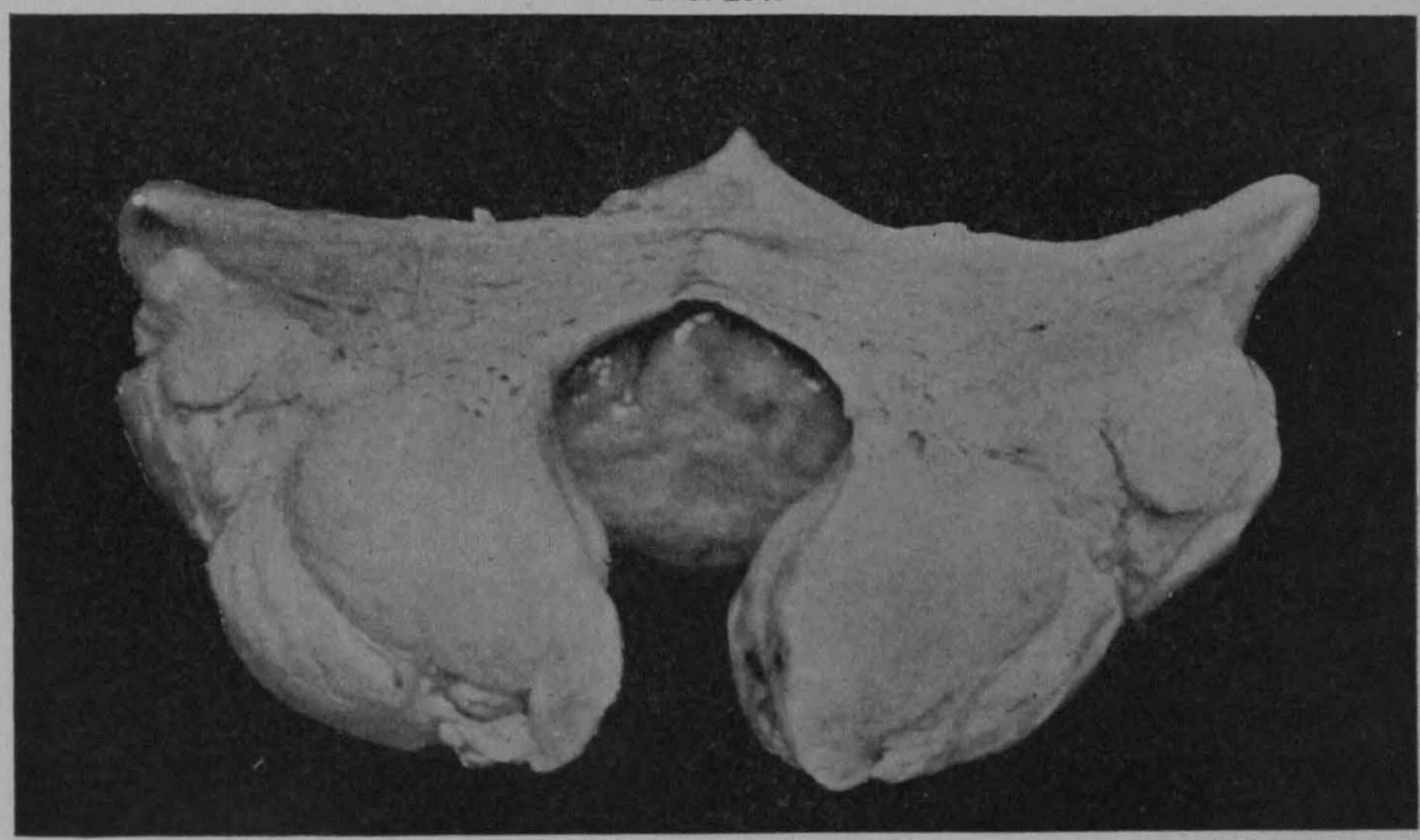

Submucous Fibroid Tumor of the Uterus: the uterus is laid open, showing the fibroid cut in two; also cavity of the uterus.

the other, more common, due to lymphangiectasis—distension of the intermuscular lymph-spaces.

Fibroid and fibro-cystic tumors occur of any size, from that of a pea to the largest, weighing one hundred and ninety-five pounds,

Fig. 237.

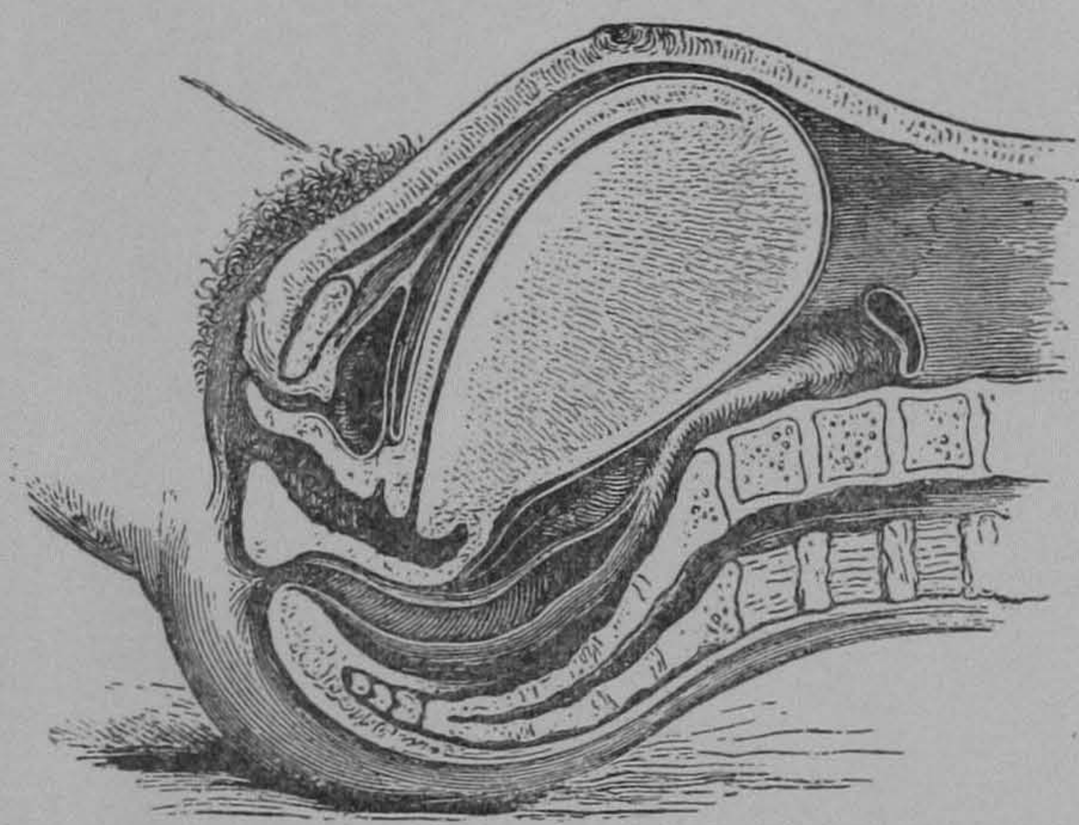

Large Fibrous Interstitial Tumor of the Uterus.

removed by Severanu. They arise from any part of the body of the uterus, and less frequently also from below the os internum. Large

Fig. 238.

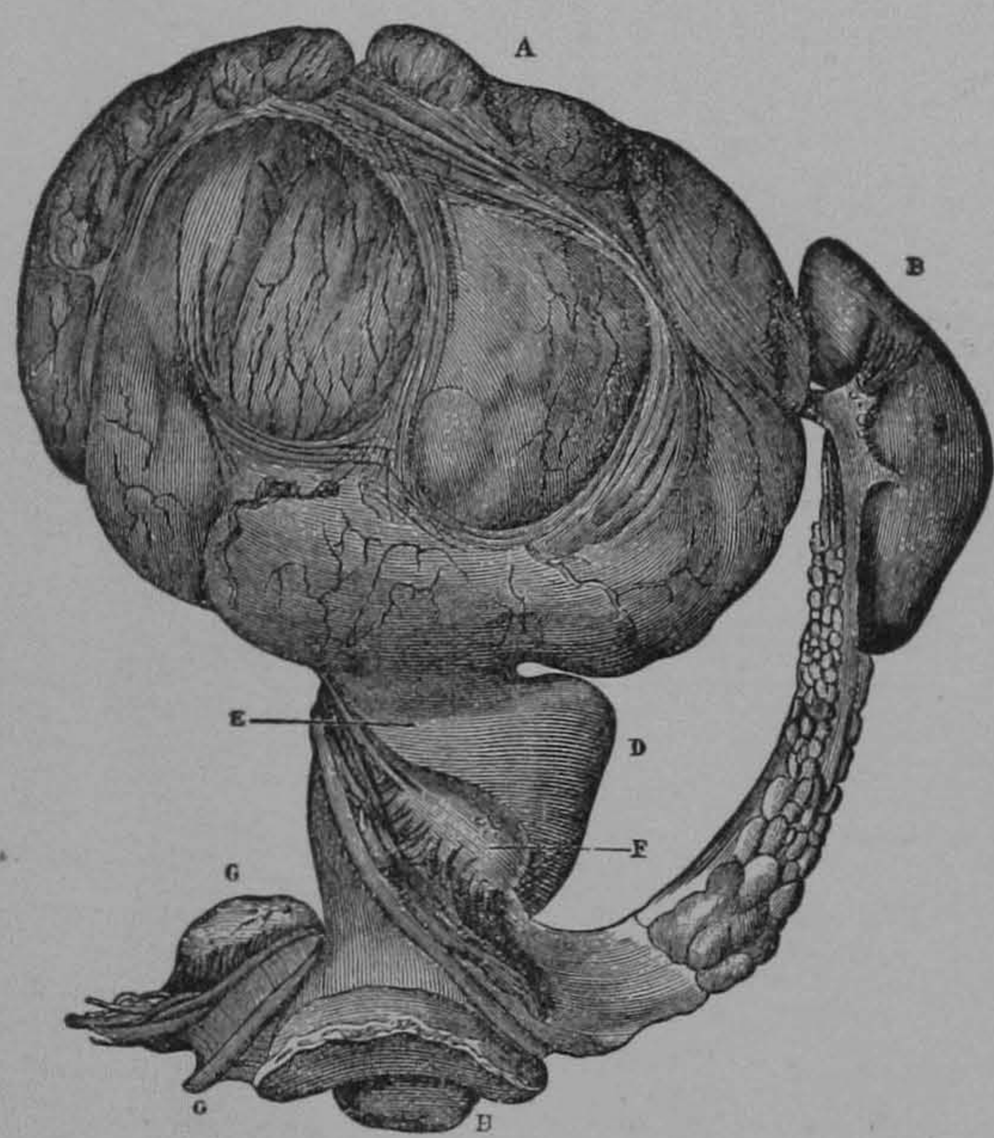

A, Subperitoneal Pedunculated Fibroid; *B*, left kidney; *C*, Wolffian cyst; *D*, interstitial fibroid contained in the right cornu of the uterus; *E*, insertion of the pedicle of the large tumor on a level with the left cornu; *F*, left ovary and round ligament; *G*, right ovary and round ligament; *H*, cervix.

subserous tumors are covered with enormous veins, and all fibroids are generously supplied with blood. According to size and locality,

FIG. 239.

Interstitial Fibroid.

they may form attachments to almost any of the abdominal organs. Pedunculated fibroids from torsion of the pedicle, may slough.

In addition to the above degenerative changes, fibroids may

FIG. 240.

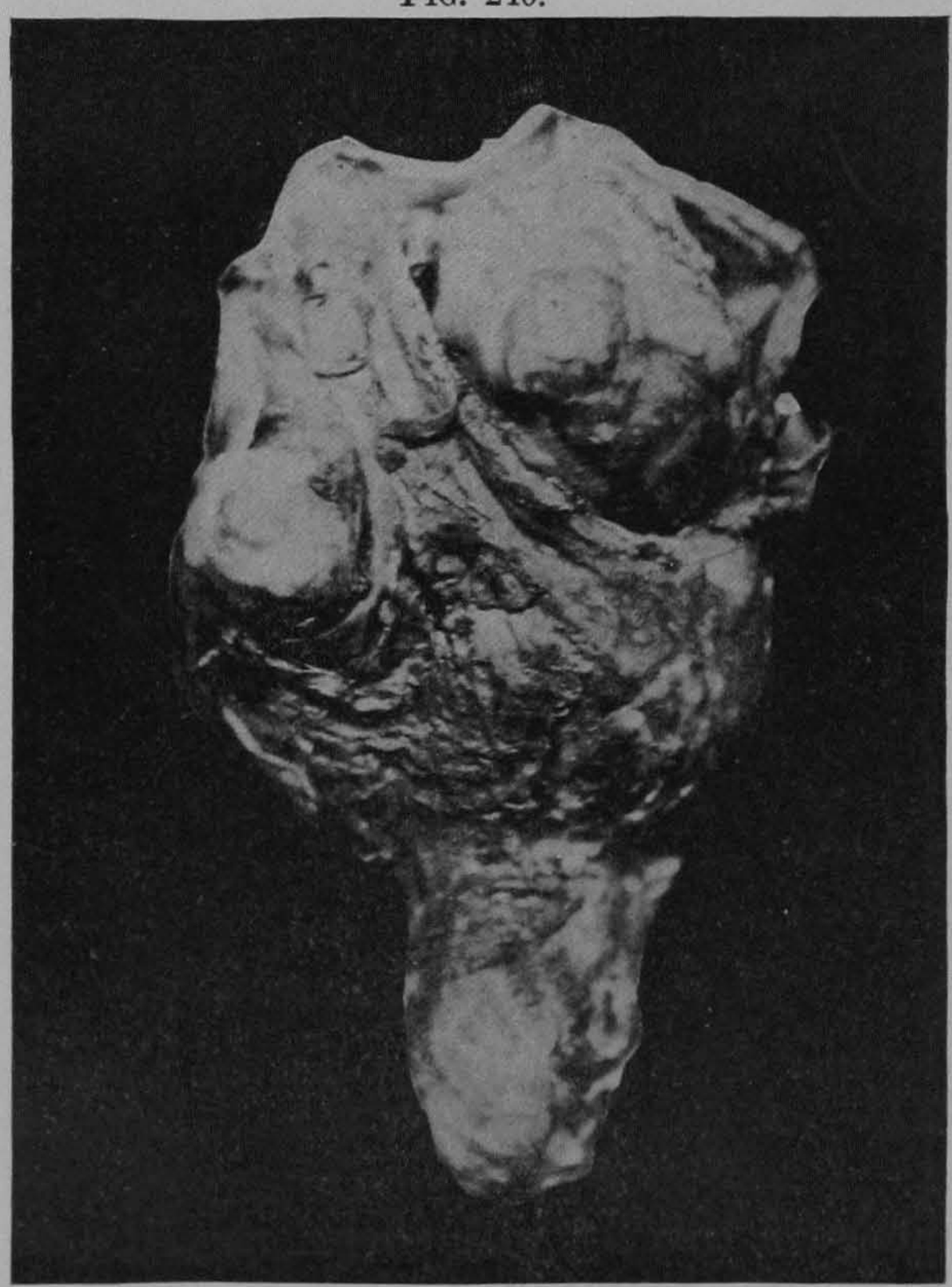

Calcareous Degeneration of Fibroma, showing the calcareous nodules.

become infected and undergo inflammation, with the production of pus, or even become gangrenous. Finally, the mucosa of the fibroid uterus may become epitheliomatous, or the connective tissue may be infiltrated with sarcomatous elements; and it is not uncommon to find cancer of the cervix coexisting with fibroid of the body. The cell-proliferation arises from the adventitia of the arteries, and the tendency to it is probably congenital.

Wyder has shown that there is nearly always an endometritis of a glandular, hypertrophic character, associated with fibroid.

Fig. 241.

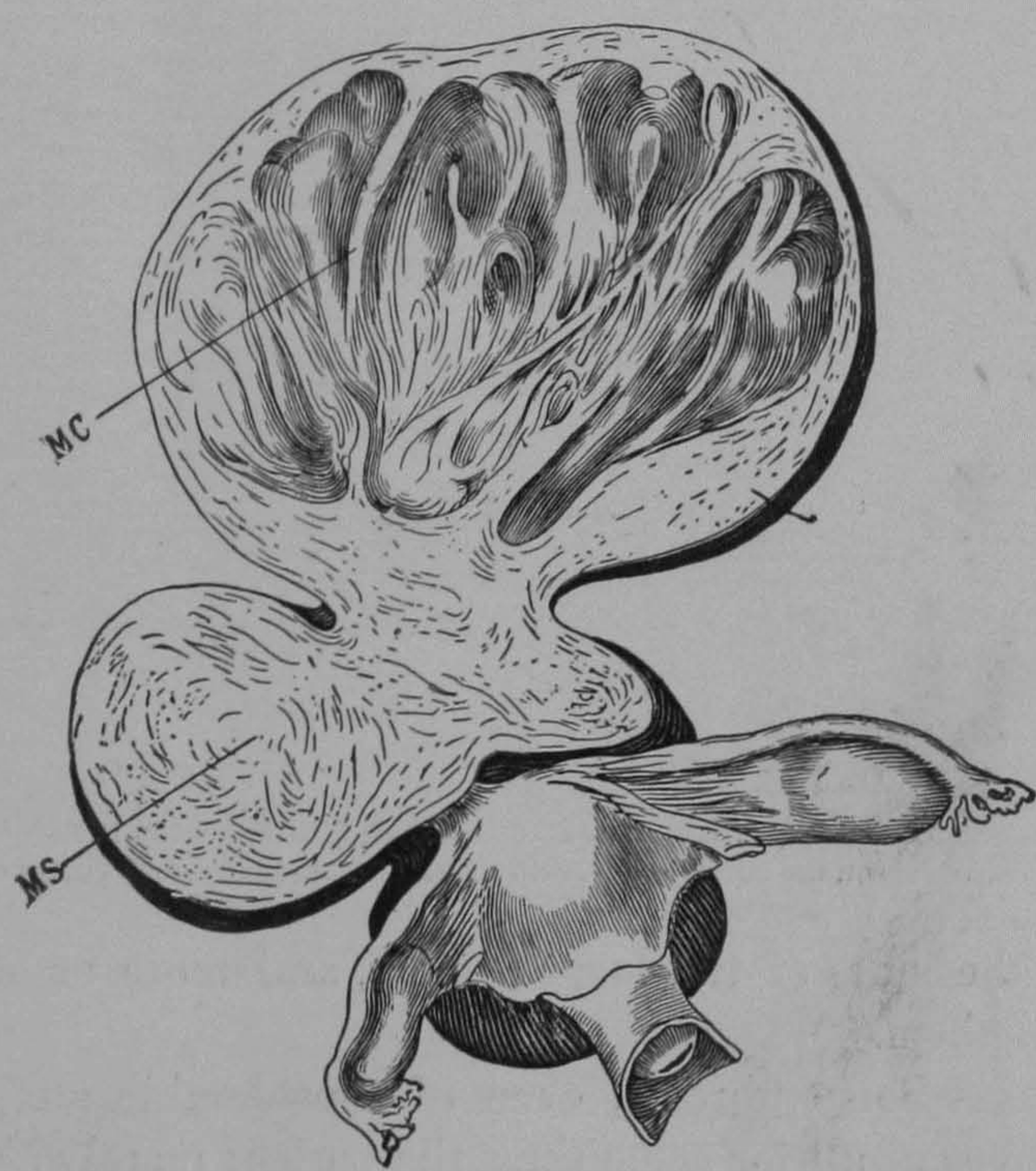

Pedunculated Fibroid with Abdominal Evolution: *MS*, fibroid lobe; *MC*, fibro-cystic lobe.

The Fallopian tubes are the seat of interstitial change also, and may contain bloody or purulent fluid, and the ovaries are usually enlarged, with thickened capsules.

Various interstitial changes are produced in the important viscera, chiefly by obstruction to the vascular circulation, as fatty liver and nephritis. Large tumors are also associated with conservative hypertrophy of the left heart. There are two forms of heart degeneration, which are supposed to exist in advanced cases, and

known as brown and fatty degeneration. Fibroids occur before middle life as a rule, and have even been noticed before puberty.

More or less peritonitis is to be found in connection with the large tumors, binding them to the viscera. The omentum especially is prone to become attached to them, thus lending to the growths a new and increased blood-supply. Large blister-like accumulations of serum often occur just under the peritoneum

FIG. 242.

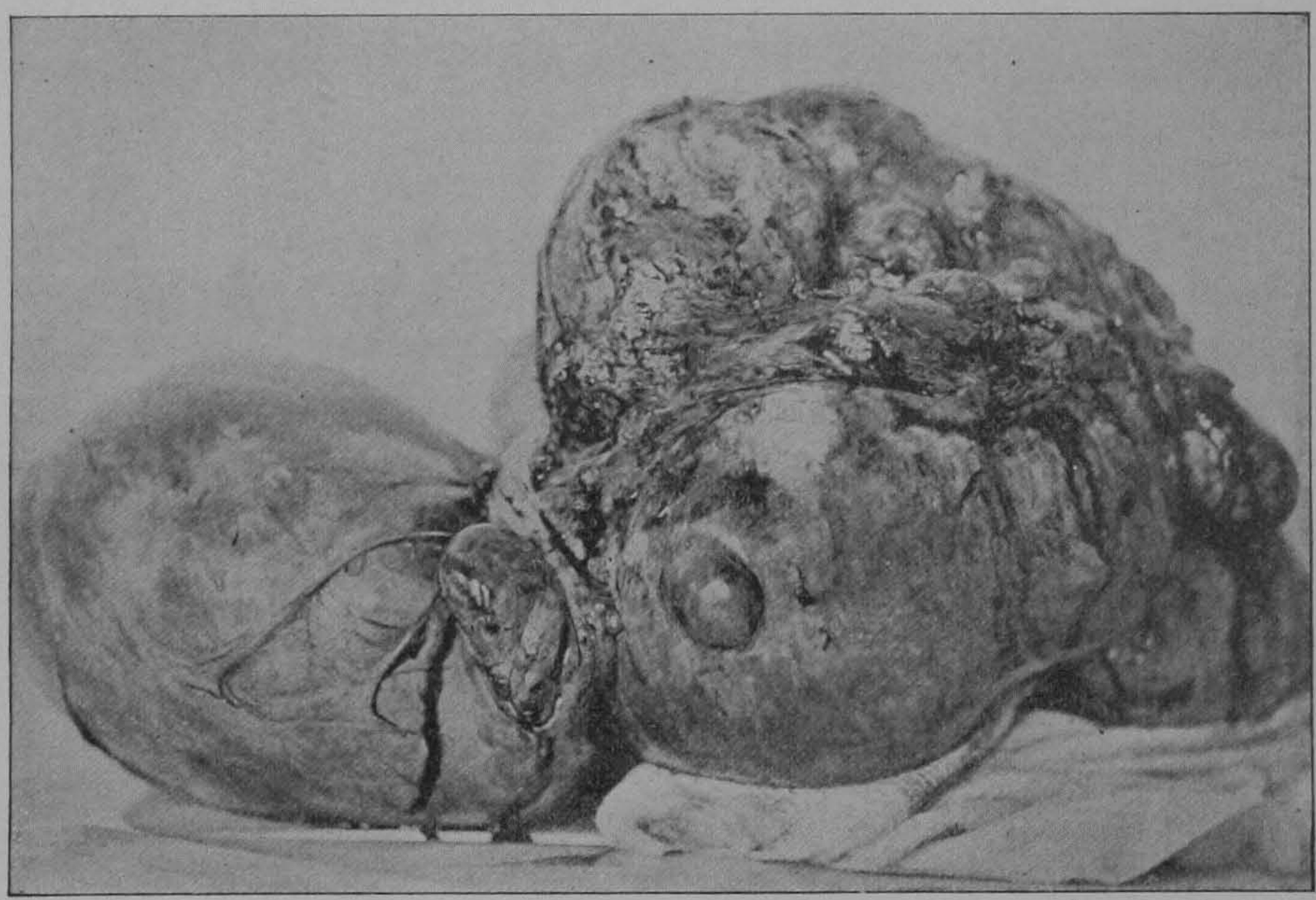

Enlarged Blood-vessels on the Surface of a Multinodular Subserous Fibroid Tumor of Uterus.

adjacent to the sides of the large tumors, and more or less ascites accompanies them.

SYMPTOMS.—Some fibroids, even of considerable size, give rise to no symptoms at all for some time, the patient merely noticing increase in her girth. Symptoms are due to the situation rather than to the size of the tumor. Subserous tumors give rise to pressure-symptoms chiefly, while hemorrhage is the most marked symptom of the submucous and interstitial varieties. But one subject may present all the various forms.

Pain.—This is very marked where the tumor causes a general distension of the uterine walls. Like all uterine pains, it is productive of hysterical symptoms. There are other pains, paroxysmal and from contraction of the uterine muscle, due to the irritating presence of the tumor. Local pain is less commonly attendant

upon the subserous variety. The greater the tension in the uterine walls, the more severe is the pain. Thus it frequently happens that there is less pain where the growth has become large and thus escaped from the control of the uterine muscle.

Tumors of size growing from any part of the uterus cause pain from pressure on the nerves and adjacent organs. These pains radiate down the thighs and through the bladder and bowels from obstructed function in those viscera. Pressure-pains are most marked with tumors which are yet in the true pelvis. When the uterus and neoplasm have risen above the brim of the pelvis, they have a greater range of mobility. Menstruation and other bleedings increase the pains markedly in some cases.

Hemorrhage.—The menstruation first begins to be increased in amount. After a while the flow is extended in time for a few days, and an observing patient will appreciate that she is using more napkins at each successive period. Soon intermenstrual bleedings occur, and at such irregular intervals that the patient will lose all record of menstruation. She will be free from hemorrhage for weeks, and then have a bleeding which will bring her to death's door. This hemorrhage is produced from the hypertrophied endometrium, which often is in a condition of general polypoid degeneration, but there may be profuse bleeding from a membrane which is atrophic. Vessels which in the normal endometrium are mere capillaries become here thin-walled arterioles. These bleedings are often the first symptoms of mural and submucous fibroids, even of those of small size. Subserous growths may attain considerable size before giving rise to marked bleeding. The occurrence of the menopause has a favorable effect upon these growths, but it often never occurs, and is always postponed by the tumor. Again, most tumors begin to produce marked symptoms at a time when the menopause should naturally occur. Moreover, the menopause may merely check the bleeding for a time, it recurring after a few years.

Alternating with the hemorrhages is a leucorrhea. This may be a simple whitish discharge, or sanious or purulent according to the changes in the endometrium. It is frequently chylous, profuse, and particularly exhausting to the patient.

Pressure-symptoms.—Tumors lying in the true pelvis obstruct the rectum, thereby producing retention of feces even for many days at a time, and inducing a form of systemic poisoning by the re-absorption of excreta—"retention toxicosis." Also, as a result

+ Sanious: thin, fetid, greenish, serous discharge

of this pressure, hemorrhoids are of common occurrence. The action of the bladder is interfered with by pressure on the urethra, producing thereby painful and difficult urination, with, ultimately, cystitis from retention.

The presence of large fibroids so obstructs the return flow of blood from the legs that there is necessarily a compensating enlargement of the veins of the abdomen. The ureters may be so obstructed as to produce hydronephrosis, and ultimately interstitial change in these glands, with albuminuria. Dropsy of the legs may occur from pressure alone, independently of kidney change.

General Symptoms.—As a result of the repeated hemorrhages these patients are exsanguinated to a considerable degree. In some the bleedings are sudden and fierce. These suffer from attacks of syncope. In others there is a continuous dribble, with occasional floodings, and they present the worst appearance of all, inasmuch as there is no interval during which recuperation may occur. Many of them are in very good flesh, some even fat. But those who have large tumors are emaciated from locking up of the emunctories and loss of appetite.

In large tumors producing pressure on the intestines there are the symptoms of anorexia, costiveness, foul breath, headache, and sometimes vomiting. Even in cases where there is no suppuration in the tumor, there may be rise in temperature; but, as a rule, febrile manifestations are indicative of degenerative changes, with production of septic material either in tumor or viscera.

Death from fibroid occurs either from asthenia, due to the continuous loss of blood and pressure, or some complication, and even from sudden profuse hemorrhage.

Diagnosis.—A. *Submucous Fibro-myoma.*—The hemorrhages are especially severe, and first attract the patient's attention. Irregular uterine colic is also frequent. If the tumor is large enough to fill the pelvis, all the symptoms due to pressure are present.

Examination is most satisfactory. The uterine canal is increased in depth. Rectal and abdominal palpation show the organ to be enlarged in all its diameters, and reveal its shape. Intra-uterine palpation is perfectly safe, and may be performed by one of two methods. That of Vulliet, by packing the uterine cavity each day with successively increasing pledgets of iodoform gauze, is efficacious, free from danger, but painful and slow. Failing to dilate the cervix sufficiently for intra-uterine examination by Vulliet's method,

incision of the cervix and forcible dilatation are to be employed. Dilatation being of sufficient extent, the finger of one hand is introduced into the uterus, while the other supports the fundus above. The submucous fibroid will be found to have made for itself a depression on that wall opposite its origin, and the tumor will be felt as a smooth, rounded body. The examination finished, the uterus is irrigated and a light drain of gauze introduced. If it has

FIG. 243.

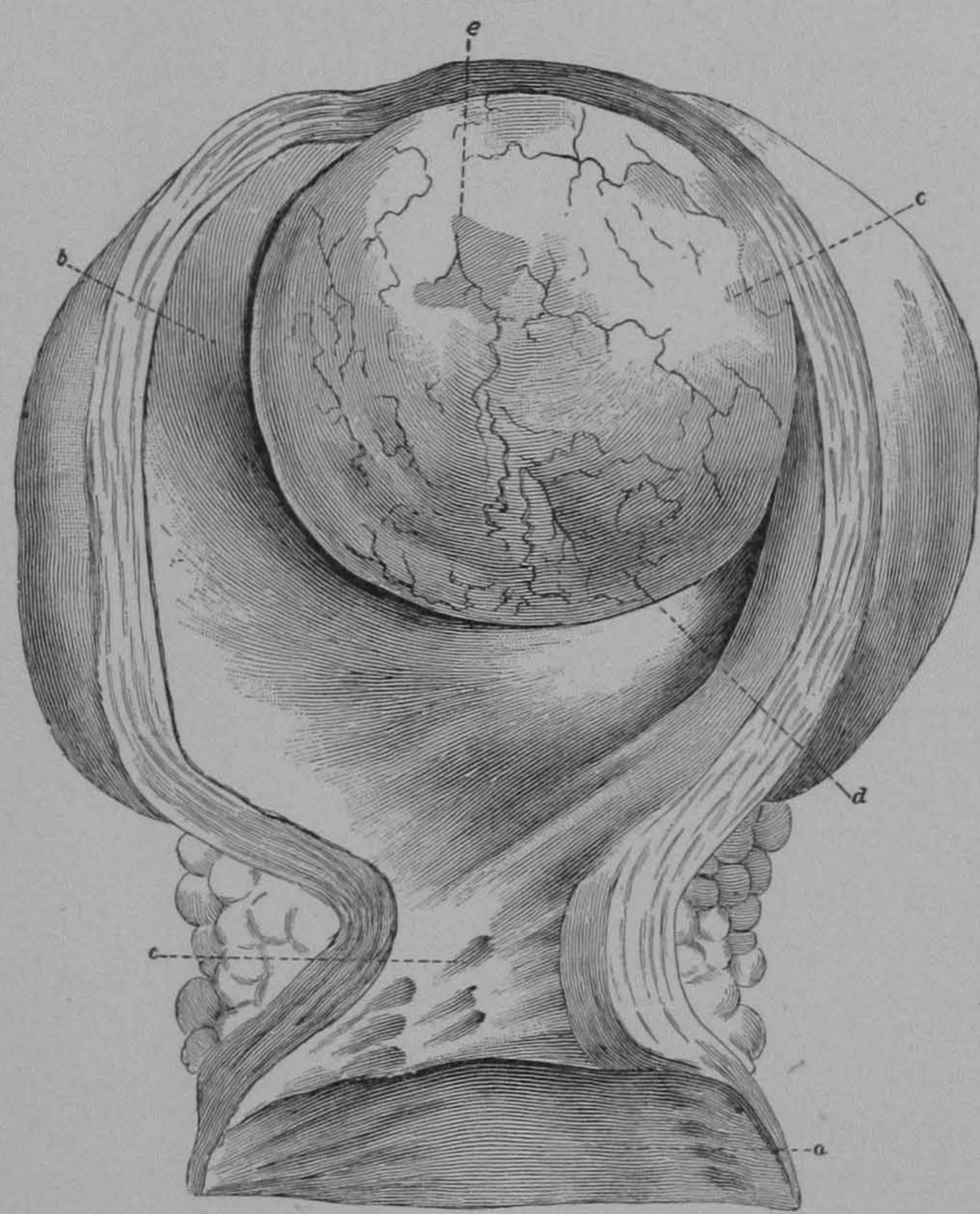

Œdematous Submucous Fibroid: *a*, portion of the vagina; *b*, cavity of the uterus; *c*, tumor lodged in the cavity of the uterus, covered by mucous membrane (*d*); *e*, tumor rising above the surface of the cavity.

been determined to remove the tumor by enucleation at a subsequent day, or if there be too free hemorrhage, the uterus should be tightly packed with iodoform gauze. In this way the cervix will be kept open for future treatment. These submucous myomata are sessile, and never pedunculated.

B. *Interstitial Fibro-myoma.*—Frequently a small tumor is accompanied by a general fibroid enlargement of the uterus, giving rise to the most severe symptoms, and yet the nodule projects into neither uterine nor pelvic cavity. The diagnosis here is difficult,

and with the enlarged uterus the symptoms point equally to carcinoma; therefore a curettage for diagnostic purposes is proper, as it enables the microscope to differentiate absolutely between the hypertrophic endometritis of myoma and the cell-proliferation of cancer. The shades of difference between aggravated hypertrophic endometritis with enlargement of the muscularis as a sequence, and general hypertrophy of the muscular walls, with a small interstitial myoma and thickened bleeding endometrium as sequences, are very slight. The chief point in distinction is the exact amount of uterine enlargement. Bimanual examination under narcosis, aided by the microscopical investigation of pieces removed by the curette, should determine the question. At least it may enable us to eliminate cancerous and tubal disease.

Where the interstitial fibroids are large, increased depth of the uterine cavity, general enlargement of the uterus, and more or less irregularity in its contour, either exterior or on the mucous coat, will suffice to make the diagnosis plain. These tumors when large produce hemorrhage, expulsion pains, and hysterical manifestations, in addition to pressure-symptoms.

C. *Subserous Fibro-myoma.*—These tumors are usually multinodular, and present a great diversity in arrangement. They may be sessile or pedunculated. The sessile tumors must be considered according to whether they extend between the layers of a broad ligament, into the bladder or into the pelvic cavity.

The diagnosis of sessile subserous fibroids projecting free into the peritoneal cavity is easy, the nodule being readily felt upon bimanual examination and rectal touch. At the same time, other conditions are easily excluded.

If the sessile fibroid grows from the anterior surface of the uterus and displaces the bladder, the uterus is usually retroflexed. The finger in the rectum may be made to feel the division between the uterus and fibroid, or the hand above the pubes may. But not always is this sulcus present, and the entire history and surroundings must be critically considered in order that an accurate diagnosis may be made.

Intra-ligamentous fibroids are exceedingly puzzling. They simulate ovarian cysts, broad ligament disease, extra-uterine pregnancy, and tubal cysts. Those which project into the broad ligament from the side are not especially difficult of diagnosis. They are more firm than other tumors in this locality, and the depression above and

below between tumor and uterus may be felt. There is not the tenderness which accompanies tubal disease, and there is more mobility when the nodule is small. Ovarian tumor, for many reasons, may be excluded. Extra-uterine pregnancy which has lasted a few months, especially if preceded by menorrhagia, is not easily differentiated from fibroid, for it has the same tense walls as fibroid. Although there is severe pain, yet it is not as lancinating as that of extra-uterine gestation, and is not followed by collapse, as in the latter. The pains of fibroid come on gradually, whereas the extra-uterine pregnancy first attracts attention by the sudden onset of the stabbing pain from the first attempt at tubal abortion. There is great difficulty in making the diagnosis sometimes, so similar are the histories of the two conditions. All fluid accumulations fluctuate, and are thus excluded.

When the sessile intra-ligamentous tumor grows down against the floor of the pelvis, it exercises violent and painful pressure upon the structures passing under it. The uterus is lifted up and immovable. The tumor is not only sessile, but also attached to the pelvic floor. Here rectal touch is especially valuable. The cervix is often so drawn upon for tissue as to be a mere ending to the vagina and cul-de-sac. So firmly attached to the pelvis are these growths that they seem to spring from the pelvic fascia. Enchondromata and fibromata of the pelvic floor have none of the general symptoms which intra-ligamentous tumors produce, and may thus be rejected.

Dermoid cysts under examination may suggest fibroid, but the subjective symptoms of the two conditions will suffice to differentiate.

Pedunculated subserous tumors float free in the abdomen with long pedicles, or are joined to the uterus by a shorter and more firm bond.

Œdematous tumors simulate ovarian cysts, but the fluctuating portions of the fibroid are limited, and there are parts of the tumor which demonstrate its character. The diagnosis is often utterly impossible. Unless the pedicle be very long and slender, the cervix grasped with the volsella and drawn down communicates at once its motion to the tumor; with dermoids and other hard cysts it does not. The area of displacement of fibroid is below the pelvic brim, that of floating kidney above. Splenic tumors arise from the splenic area and may be traced to their origin. Cancerous and

tubercular omental disease displaces the stomach downward, and there is no area of resonance save at the hypogastrium. The growth is more rapid than in fibroids, and hemorrhage is wanting.

Many large fibroid and fibro-cystic tumors never give rise to hemorrhages, and the first and sole symptom may be the presence of the tumor. This is especially true of the fibro-cystic tumors, they causing, compared with the true fibro-myoma, but little bleeding. They have taken some time to grow, and coils of intestine are commonly in front of them, giving a tympanitic percussion-note. Almost invariably the cavity of the uterus is increased in depth, and rectal touch at least will demonstrate the attachment of the tumor to the uterus.

TREATMENT.—Sometimes tumors are accidentally discovered, produce no symptoms, and never give rise to conditions requiring treatment. They remain innocent during all the woman's life.

The treatment may be divided into non-operative and operative. In the former class we shall mention but two methods of treating these growths—by the use of ergot and by electricity.

Ergot Treatment.—The ergot is used both hypodermically and by the mouth, and is employed in every form of the tumor—in subserous fibroid for the purpose of causing shrinking, and in interstitial and submucous growths not only to cause diminution in size, but also, possibly, to cause expulsion of the growth *per vias naturales.*

Squibbs's aqueous extract (ergotin), dissolved 1 part to 10 of water, and 1 grain of salicylic acid added to each half-ounce of solution, the whole sterilized, may be employed with a hypodermic syringe kept for that purpose. The syringe also should be carefully sterilized before each application.

Beginning with 1 grain a day, the dosage may gradually be increased, the uterine pain governing largely the amount used. The same preparation may be used in pill form associated with nux vomica or strychnia. Where the tumor is submucous and interstitial large doses of ergot produce sudden and severe uterine colic; not so much impression is made, however, upon pedunculated fibroids. The depressing action of ergot upon the heart should not be forgotten, and for that reason it is wise to use strychnia at the same time. It is better to use a moderate dose continuously with weekly increases than to give enormous doses and intermit.

Thus, if a patient receives internally 3 grains of ergotin a day and 1 grain hypodermically one day in the week, she should take enough to cause marked effect upon the uterine muscle.

There can be no question as to the effect of the drug. The most careful observers are unanimous in testifying that it not only relieves symptoms, but in all cases reduces the tumor, and a number of cases are reported of the voiding of tumors under its use. There is but little danger in its use, and we have been able to find only two cases which died while undergoing this treatment. Hydrastis canadensis is also highly spoken of as a substitute for ergot, in doses of 20 minims of the fluid extract, three times a day.

Ergot has no effect upon the fluid contents of fibro-cysts.

Electricity.—The electrical treatment of fibroids is so technical, and requires such an assortment of instruments and batteries, that information on the manner of using it will be left to special works on the subject. Different authors give different instructions as to the strength of the current: they range from 15 milliampères to 250, or even more. The pain produced by the strong currents is excessive. As to the results of the procedure, the latest figures are given from the works of Keith, Englemann, Gautier, and others who are particularly skilled in the method. There were 372 cases: 9 cured, 5 died. This is 2.4 + per cent. cured and 1.3 + per cent. died — too high a ratio of mortality and too low a ratio of cures. The percentage of cures about represents the possible percentage of errors in diagnosis. There is another certain percentage not mentioned here, but which is, under careful investigation, growing. We refer to malignant disease associated with fibro-myoma. Electricity is admittedly not applicable to any form of cystic fibroma.

Altogether, the method must be considered purely experimental. The above results are certainly not flattering. Surely better results have been obtained from the use of ergot, and infinitely better from the removal of the uterine appendages, with about the same rate of mortality. In all cases where the physician feels he would not care to attack these growths radically, in view of the poor results at the hands of those who are masters of the electrical method, we would certainly recommend the use of ergot or hydrastis to the exclusion of electricity, supplemented also by curettage in cases with severe hemorrhage, the results on both the tumor and general economy being excellent.

The treatment of fibroids by galvano-puncture is no longer

practised to any extent, and is to be condemned in an uncompromising manner.

Surgical Treatment.—Vaginal Enucleation.—This operation may be applicable to tumors which may pass the pelvic outlet or those not larger than the fetal head. The method is limited to growths which are strictly submucous or covered by only a small quantity of muscular tissue. The cervix is to be dilated by daily packing with gauze, and at the time of operation its calibre may be still more increased by incisions and forcible dilatation. The operation is preferably done in the dorsal position. The patient should be prepared as for a hysterectomy. If there be not room enough, the uterine artery may easily be ligated (see Vaginal Hysterectomy), and the cervix split to the vaginal junction. The tumor being located, its capsule is seized with a bullet forceps and split with a scalpel from above downward. A blunt-pointed curved scissors is then used to loosen the capsule from the circumference of the tumor. The excess of capsule is then cut off with scissors. The tumor is now

Fig. 244.

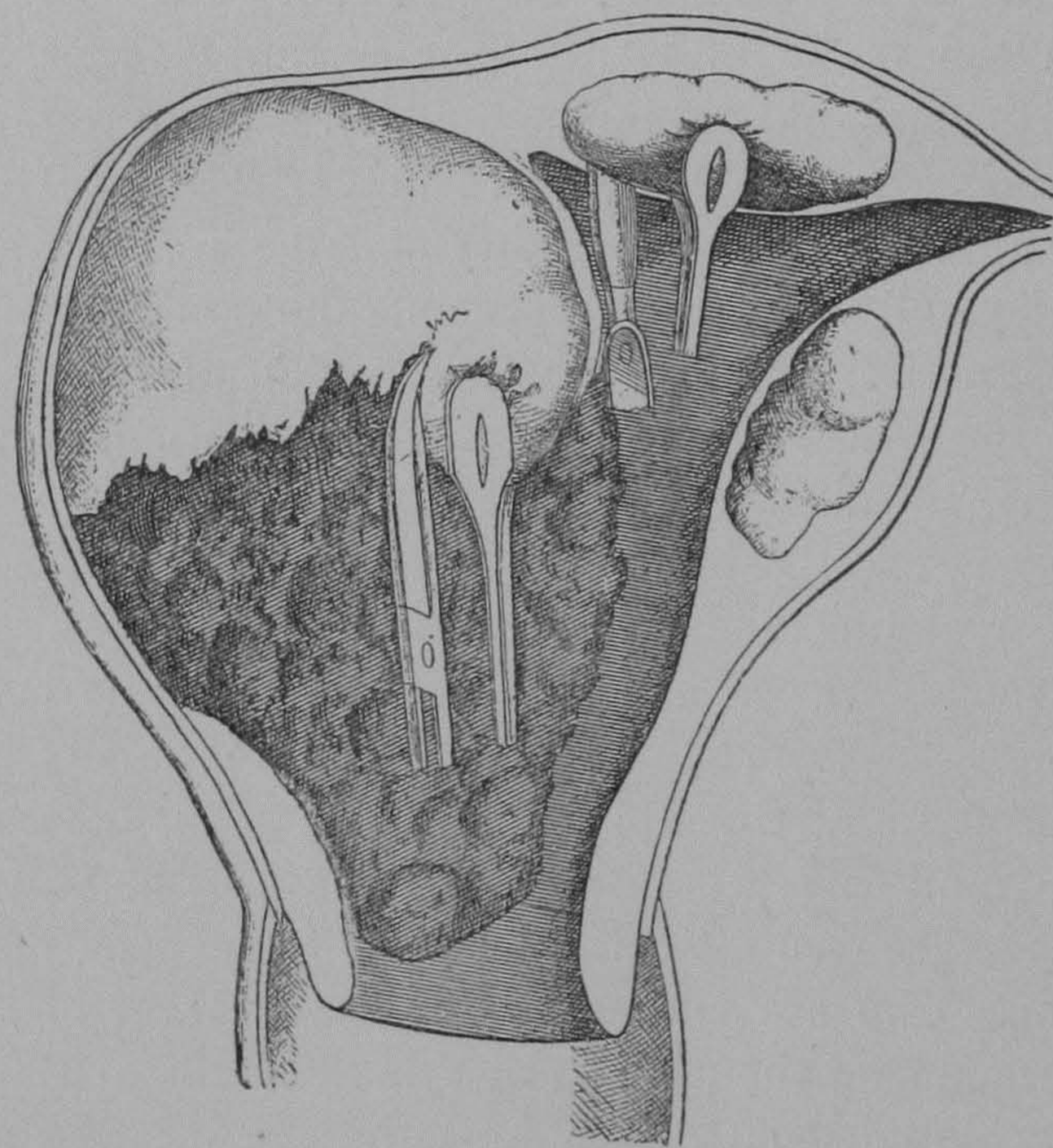

Removal of Fibroma by Morcellation.

seized with the forceps, and attempts made to dig it out of its bed with the blunt scissors, the point being turned toward the tumor.

In this way, alternately snipping connecting fibres and using either the closed scissors or an enucleator, but all the time applying firm traction on the tumor, it may be loosened from its bed, with the exception of a few fibres. It is then seized with a pair of strong forceps or hysterectomy volsella and twisted off. If the mass will not pass the cervix, it may be split. All loose shreds of tissue and capsule

Fig. 245.

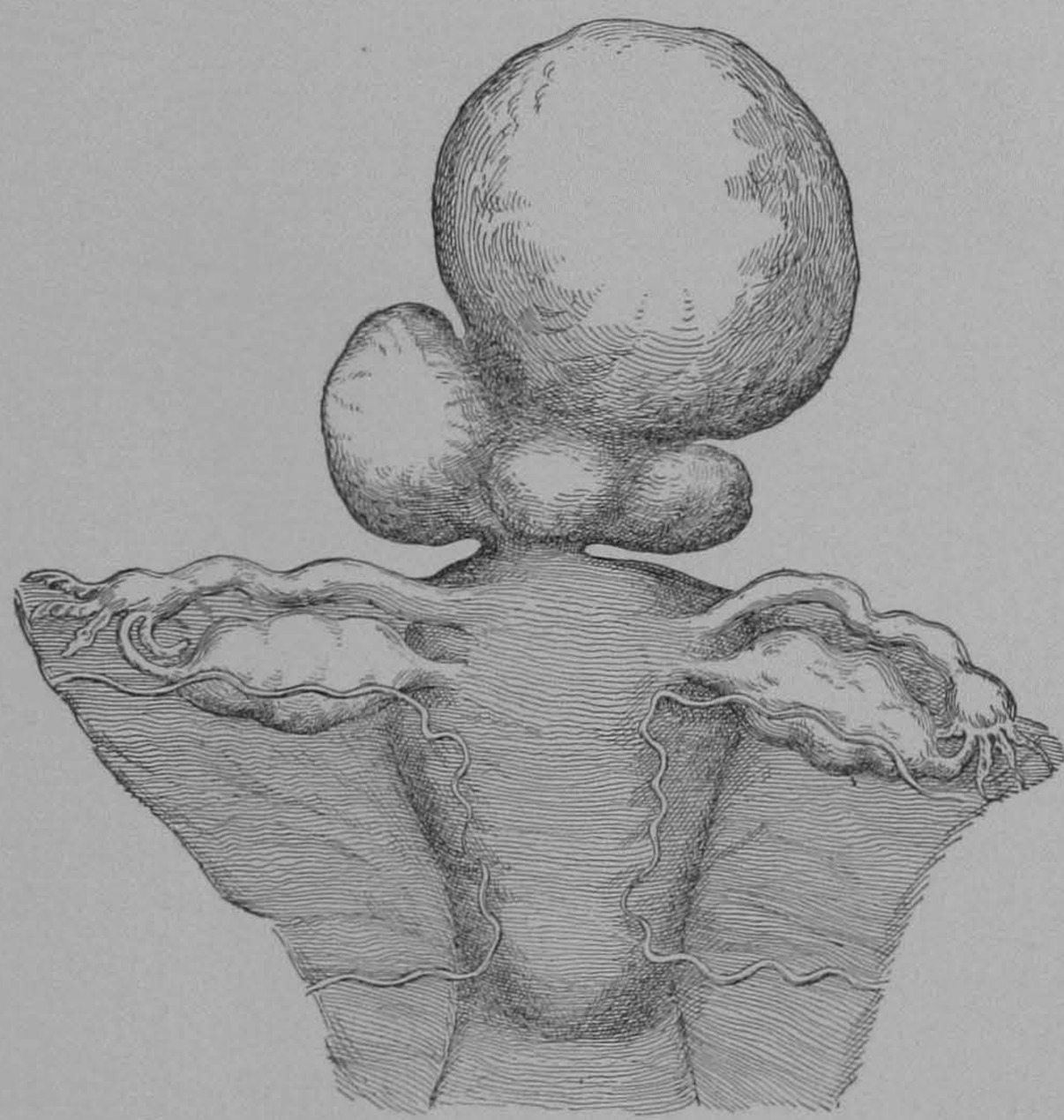

Subperitoneal Nodular Fibroid Tumor of the Uterus.

should be cut away, the finger introduced to see how much damage has been done, and the uterus washed out and packed with iodoform gauze. The hemorrhage is best controlled by the packing. The great danger from this operation has heretofore been sepsis, a thing we can now avoid. Even perforation of the uterus is not especially dangerous. Many tumors now removed by hysterectomy were formerly dealt with by this procedure. The after-treatment consists of the administration hypodermically of ergotin, frequent irrigation, and gauze packing invariably instead of drainage tubing. Most tumors formerly subjected to this operation are now preferably extirpated from above.

Applicable to tumors of the submucous and interstitial variety, *morcellation* will never occupy a place in surgery. It essentially involves incomplete piecemeal removal of the growths by forceps,

scissors, and knife, after severe preliminary incisions in cervix and uterus.

Small interstitial fibroids may be removed by total vaginal hysterectomy. The operation may be indicated when the mass is very

Fig. 246.

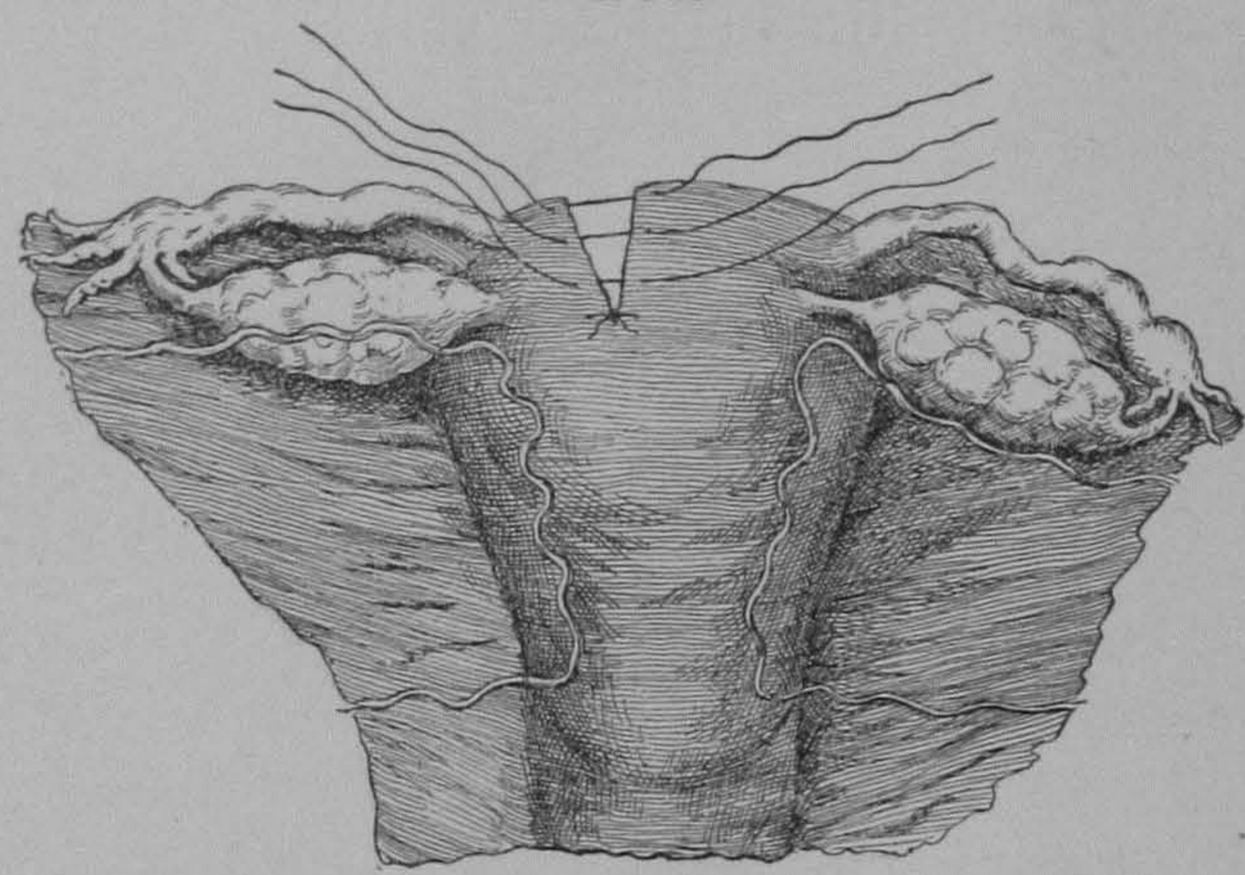

Method of Removal of a Subserous Uterine Fibroid, stitches in place ready for tying.

small, gives great pain, which produces profuse bleeding, or is septic. Cœliotomy is, however, preferable, as a general rule.

Myomectomy.—It will occasionally happen that the fibroid is attached to the uterus by a pedicle so small as to warrant removal of the tumor through the abdominal incision, with the saving of the uterus. The pedicle is subjected to a V-shaped incision and the tumor removed. Sutures of heavy silkworm-gut or silk are then used to unite accurately the sides of the pedicle. If there is complete control of the bleeding without the appearance of strangulation by the sutures, the uterus is returned and the abdomen closed. Large pedunculated fibroids with stout pedicles may be treated differently, thus eliminating the great danger of myomectomy—hemorrhage. An elastic ligature or écraseur is thrown around the pedicle a little distance from the uterus, and the tumor cut away. The pedicle is brought up into the wound, transfixed with stout pedicle needles, and the wound accurately closed around the stump, thus treating the stump extra-peritoneally. (See Supra-vaginal Hysterectomy.)

The procedure may also be applicable to small (single or multiple) interstitial fibromata. The objections to myomectomy are, that uterine fibroids are almost universally multiple, and, no difference how many nodules are removed, the chances are largely that others have

been unobserved and left behind to reproduce the trouble. In the vast majority of even small interstitial fibromata the complete enucleation of the tumors is a matter of great difficulty and results in much traumatism. The causes which in the past have rendered hysterec-

FIG. 247.

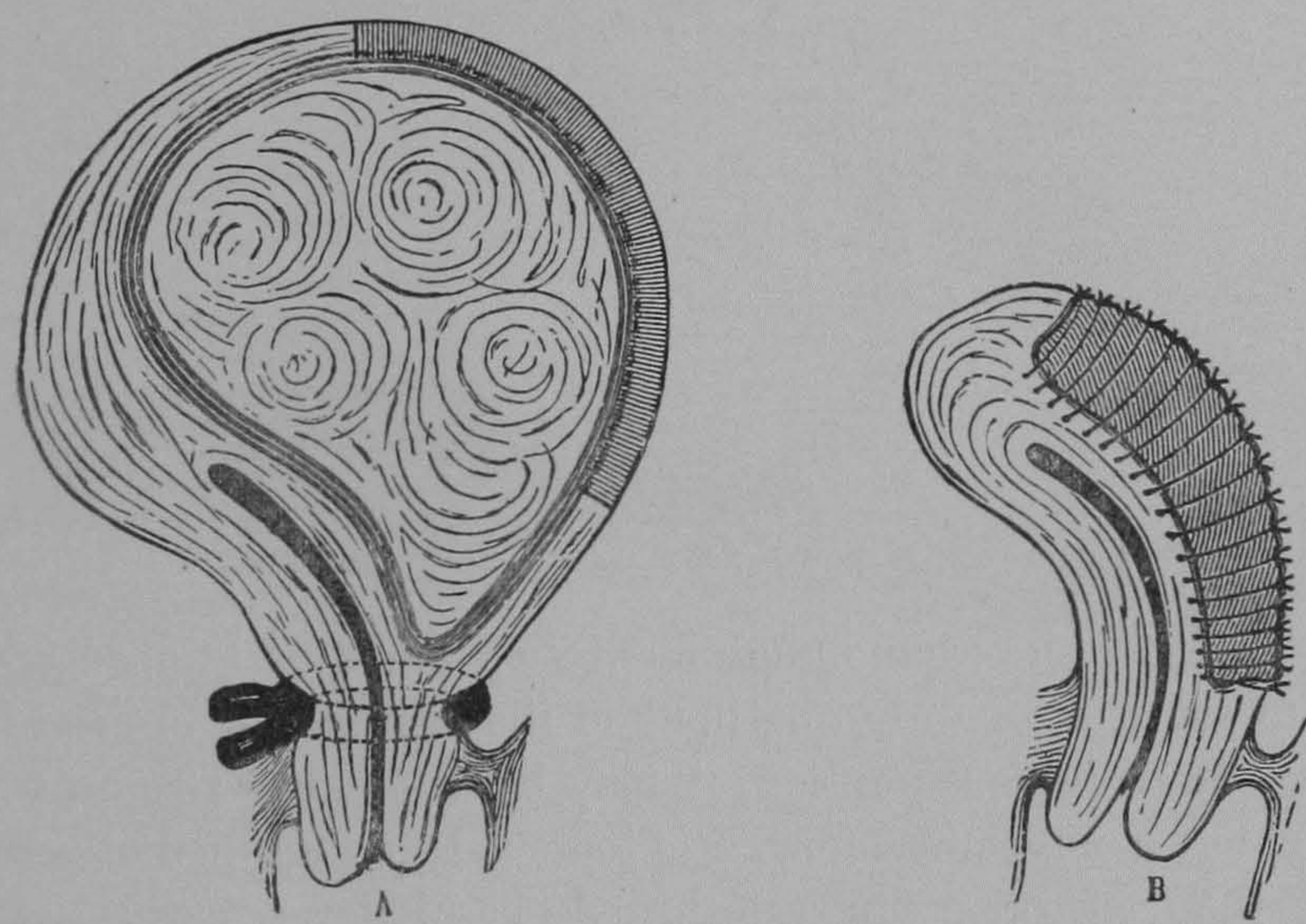

A, Enucleation of an Interstitial Myoma: B, Disposition of Sutures after Enucleation.

tomy so fatal are present in myomectomy—*i. e.* the great difficulty, almost impossibility, of placing stitches in uterine tissue with any degree of security.

Supra-vaginal Hysterectomy. — Extra-peritoneal Amputation Method.—This necessitates the treatment of the stump extra-peritoneally. The abdomen is opened and the uterus and tumor are turned out through the incision. If necessary to accomplish this, the broad ligaments are ligated between two ligatures and a rubber ligature drawn taut, or an écraseur is applied around the neck of the uterus. In fastening the rubber ligature one knot is tied and a stout silk thread is thrown over it; then the second knot in the rubber ligature is tied, and the silk thread tied over this second knot. The same may be accomplished by grasping the knot in the bite of a pair of hemostatic forceps. Thus slipping is prevented. If the écraseur is used, it is carefully tightened. The peritoneum two or three inches above the constricting wire is incised completely around the tumor, the broad ligaments being by this means allowed to retract. The tumor is then drawn further up out of the incision, thus forming a smaller and better pedicle. Transfixion pins are made to per-

forate the pedicle immediately above the wire, and the tumor is cut away about an inch above the pins. The stump is held high in the

FIG. 248.

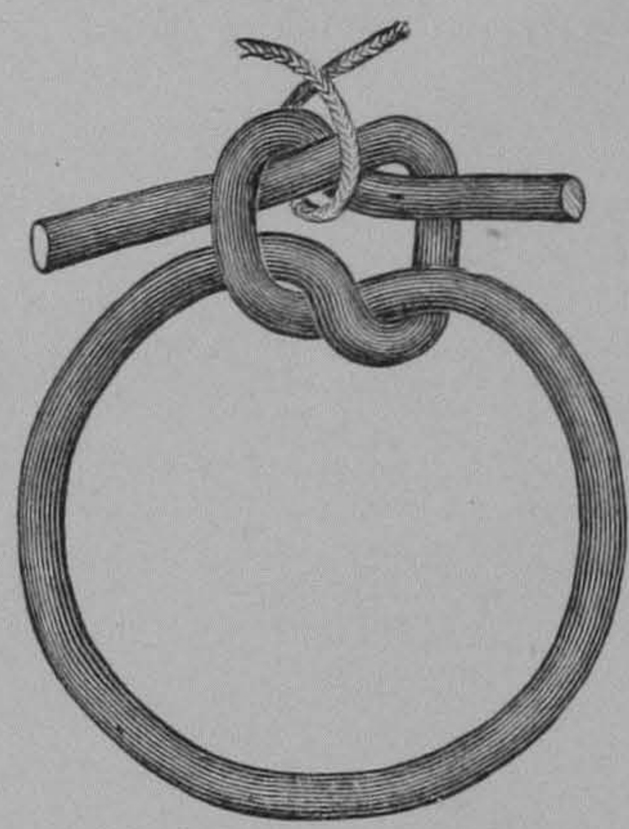

Knot of Rubber Ligature secured from Slipping by Application of Silk Ligature.

lower angle of the wound, and inspection made of the constricting wire to see that it does not include the bladder or ureters in its grasp. If in proper position, it may be allowed to remain permanently, but if not satisfactory, it is loosened and applied at a higher level; the transfixion pins are shifted to a higher point at the same time. Should the stump be too large, it must be reduced to a size

FIG. 249.

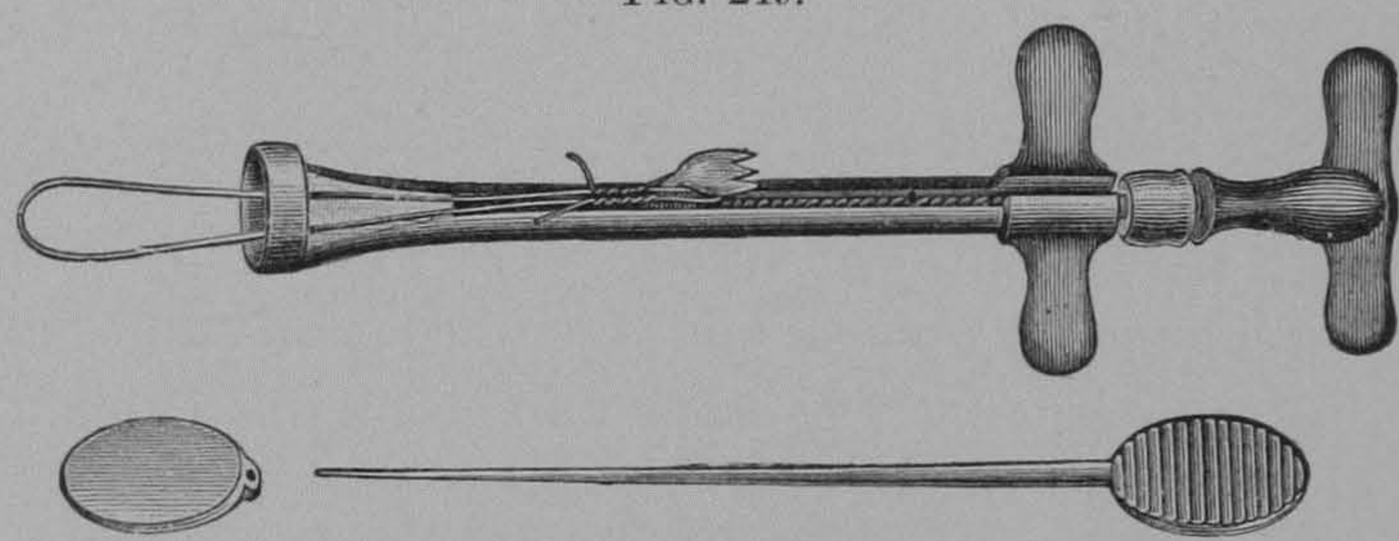

Serre-nœud for Hysterectomy.

not greater than an inch or two in diameter by cutting the muscular and fibrous portions away piecemeal, the wire being carefully tightened during the procedure. The peritoneum is then closed by stitching it to the serous surface of the pedicle below the wire, by means of a single silk or catgut suture. The peritoneum of the pedicle is closed by drawing it up over the stump by means of a continuous whipped silk suture. Throughout the whole procedure the écraseur is continually tightened by turning the screw. Unless this precaution be observed the tissue of the stump shrinks under the

PLATE XIX.

FIG. 1.

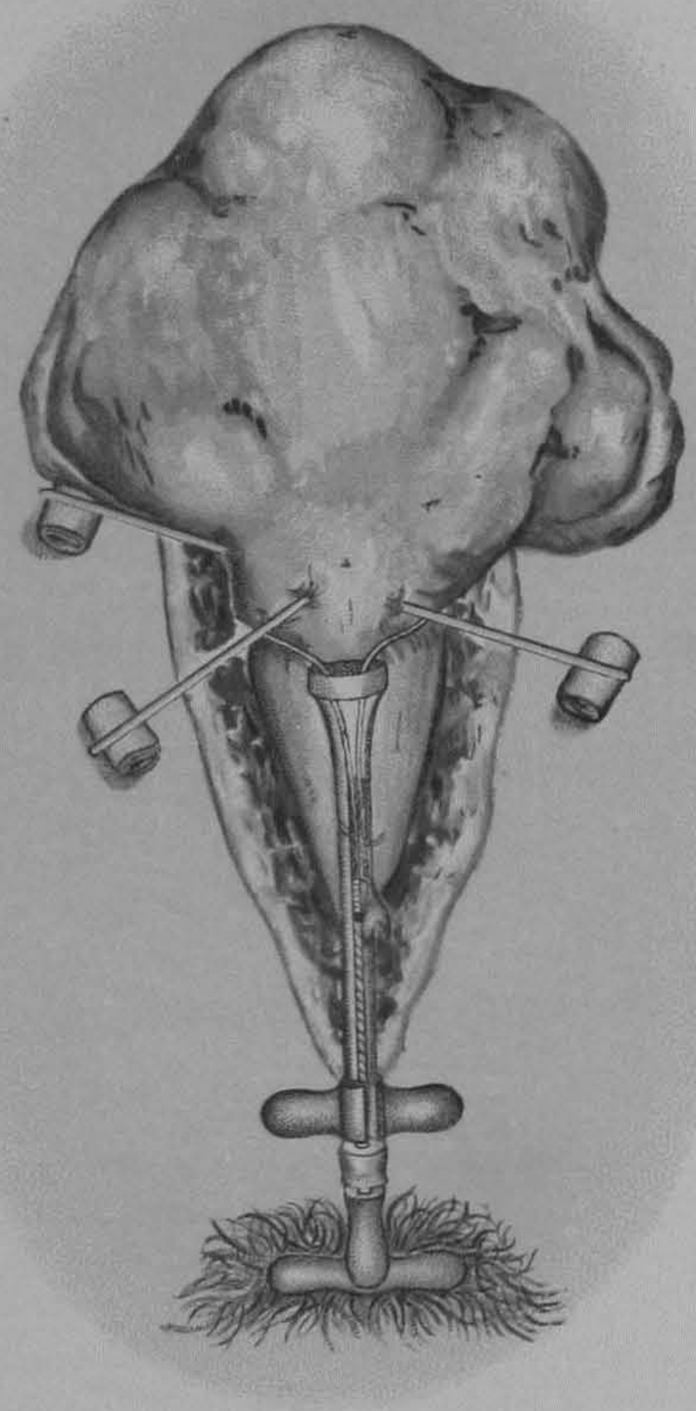

FIG. 2.

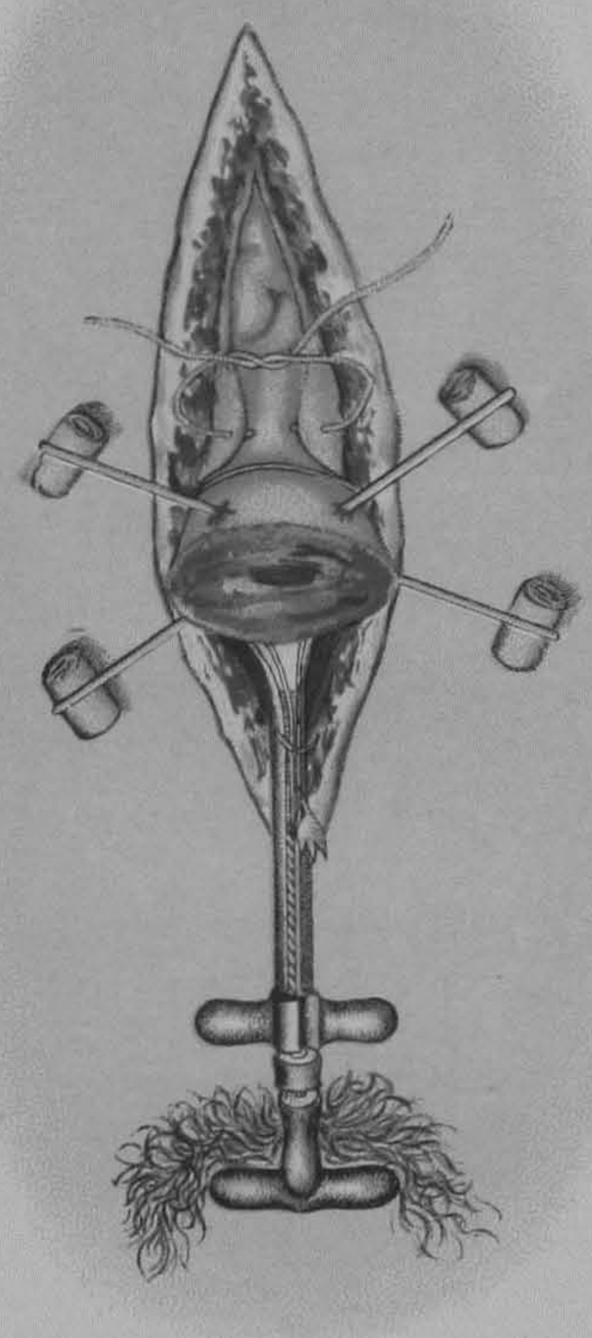

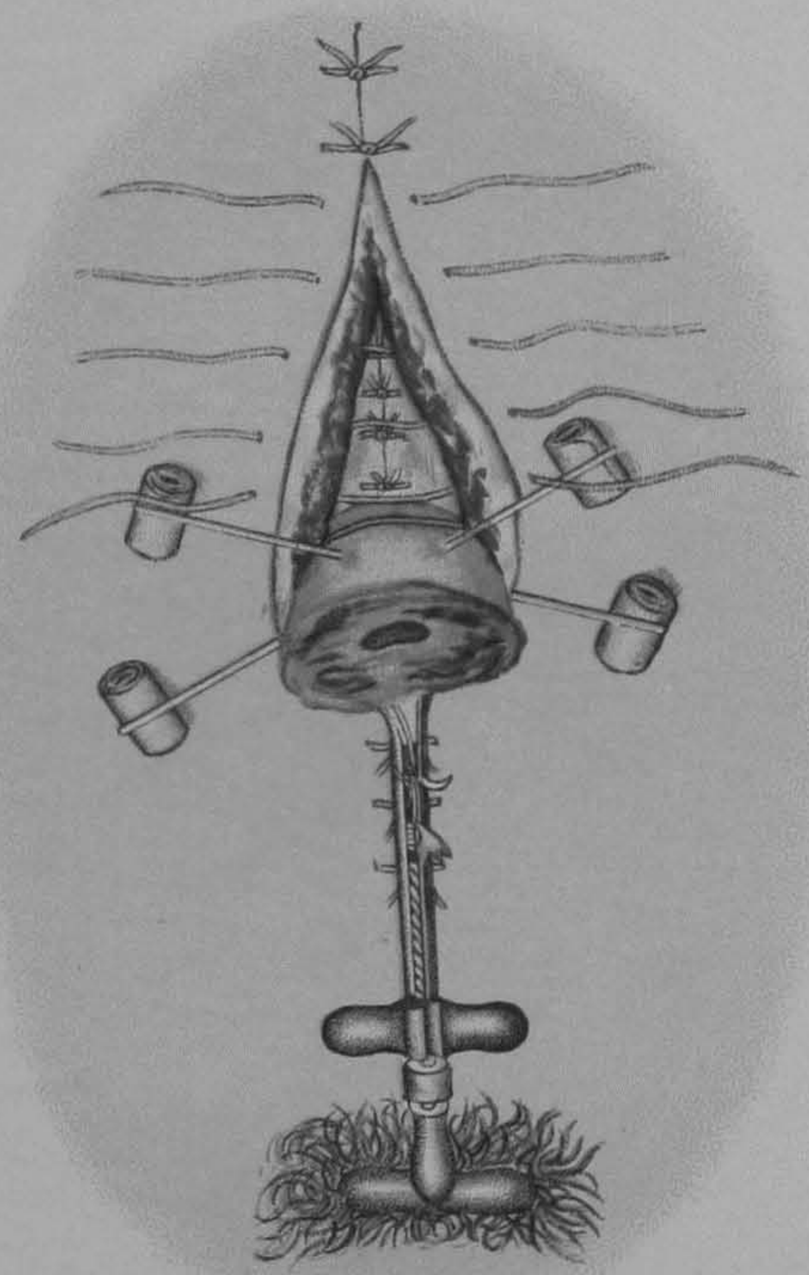

FIG. 3.

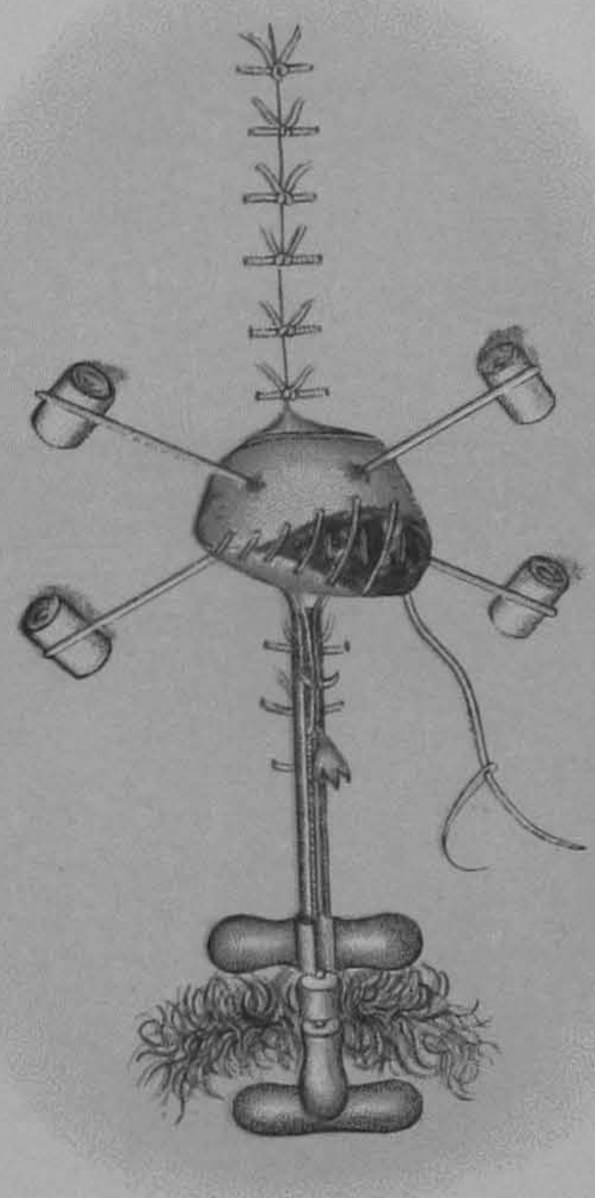

FIG. 4.

EXTRA-PERITONEAL TREATMENT OF THE STUMP AFTER SUPRA-VAGINAL HYSTERECTOMY.

FIG. 1.—Transfixion pins and serre-nœud in place prior to removal of tumor.
FIG. 2.—Abdominal peritoneum stitched to peritoneum of stump below wire.
FIG. 3.—Peritoneum closed; abdominal stitches in place.
FIG. 4.—Abdominal wound closed; stump in process of closure.

Jamie L. Furrh, MSIS
Digital Projects Librarian
Gibson D. Lewis Health Science Library

UNIVERSITY *of* NORTH TEXAS
HEALTH SCIENCE CENTER
at Fort Worth

★

Education, Research,
Patient Care *and* Service

3500 Camp Bowie Boulevard
Fort Worth, Texas 76107-2699
817-735-2588 Fax 817-763-0325
800-687-5302
jamie.furrh@unthsc.edu
http://library.hsc.unt.edu
http://digitalcommons.hsc.unt.edu

pressure of the wire, and bleeding would soon occur. If the rubber ligature be used, this precaution need not be observed. The abdominal walls are closed in the usual way by interrupted silkworm-gut sutures, passing through all the tissues but the serosa. After the stump and surroundings have been thoroughly dried an iodoform gauze dressing is applied. Pads of gauze are slipped between the transfixion pins and the skin, and are also packed carefully about and over the stump, iodoform having been freely dusted over and rubbed into the stump. The whole is covered with a thick gauze pad and held in place by a three-tailed abdominal binder.

This operation can be performed very rapidly, and may be applicable to all tumors with the exception of those which burrow between the broad ligament folds, and septic tumors, where the sepsis involves the neck or pedicle. The pedicle dries up and gradually melts off into the dressings or comes away as a solid mummified mass. The first dressing is made on the eighth day, when the stitches are removed, the écraseur having been kept tight by turning the key several times daily. The stump is ready to come off in from two to three weeks. If it does not come away itself in that time, it is best to remove the wire and pins and cut it away.

The stump sinks deeply into the pelvis, leaving a tube of granulating tissue, which is packed with gauze and which gradually closes. The question of drainage must be settled by the necessities of each individual case. As a rule, it is unnecessary.

There is, of course, a break in the parietes at the position of the pedicle which may subsequently form a hernia; these patients should wear an abdominal pad, and should be kept in bed not less than six weeks or two months after the operation. Occasionally also a fistulous opening may remain from the cervical canal to the incision, through which air may pass up and down on exertion; this is, however, of rare occurrence, the greater danger being that of hernia.

Intra-abdominal Amputation Method.—The patient is placed in Trendelenberg's position, the abdomen opened, and the tumor delivered if possible. If this cannot be accomplished, the first steps of the operation are carried out with the tumor *in situ.* A single ligature is passed through the broad ligament near the pelvic wall and tied, not being passed deep enough to include the uterine arteries. Another ligature is made to transfix the broad ligament near the uterus, and tied. The tissue between these two ligatures is cut through, and the same procedure is repeated on the opposite side. In this ma-

to avoid any possibility of including the ureter in its grasp. The

Fig. 250.

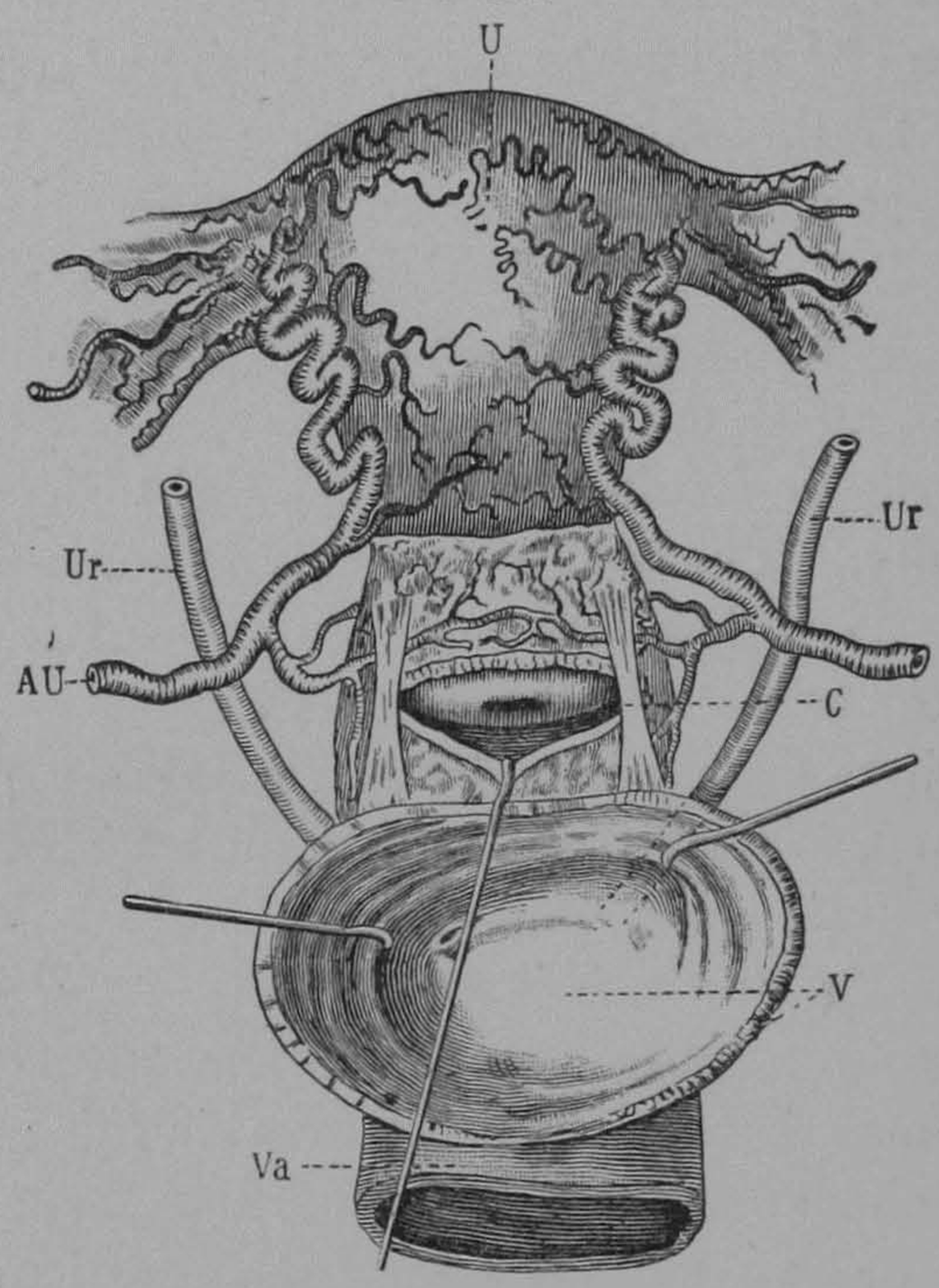

Relation of the Ureters and Uterine Arteries to the Cervix: *U*, uterus; *Ur*, ureter; *A U*, uterine artery; *C*, cervix uteri, displayed by a transverse incision of the anterior vaginal cul-de-sac; *V*, section of the bladder at the level of the entrance of the ureters through its walls; *Va*, vagina: two bands of fibrous tissue are seen to unite it laterally with the uterus. We can distinguish in the cervix the part not covered by peritoneum which adhered to the bladder before dissection.

ligature may be passed between the flaps of peritoneum thus formed or outside of them. One is placed on each uterine artery and is securely fastened. This is the most important step in the operation. The tumor is now amputated on a level with the ligatures on the uterine arteries by a V-shaped incision, the point of the V being carried well below the point of ligation. (See Plate XX.) The cervical canal is charred with a Paquelin cautery or disinfected with a bichloride-of-mercury solution, in order to avoid any chance of septic infection from that source

PLATE XX.

FIG. 1.

FIG. 2.

FIG. 1.—Supra-vaginal Amputation of the Uterus: first step. Position of second ligature shown.
FIG. 2.—Supra-vaginal Amputation of the Uterus: cervix amputated by wedge-shaped incision.

Jamie L. Furrh, MSIS
Digital Projects Librarian
Gibson D. Lewis Health Science Library

UNIVERSITY of NORTH TEXAS
HEALTH SCIENCE CENTER
at Fort Worth

Education, Research,
Patient Care and Service

3500 Camp Bowie Boulevard
Fort Worth, Texas 76107-2699
817-735-2588 Fax 817-763-0325
800-687-5302
jamie.furrh@unthsc.edu
http://library.hsc.unt.edu
http://digitalcommons.hsc.unt.edu

during the subsequent manipulations. The cervical flaps thus formed are now brought together with a continuous suture, which, after closing the cervix, is carried along, whipping the cut edges of peritoneum together from one side of the pelvis to the other. (See Plate XXI.) By this procedure the cervix, the two ligatures on the uterine arteries, and at times even the ligatures on the ovarian arteries, are turned under the peritoneum, thus becoming extra-peritoneal. The abdomen is closed without drainage.

In *intraligamentous fibroid tumors* or bad (chronic) pelvic inflammatory conditions a modification of this procedure is at times invaluable. The modification is, however, accompanied by such technical dangers and difficulties that as a routine practice—excepting in the hands of an expert—it is not to be employed. It should never in the inflammatory cases be the method of choice, but always that of necessity.

FIG. 251.

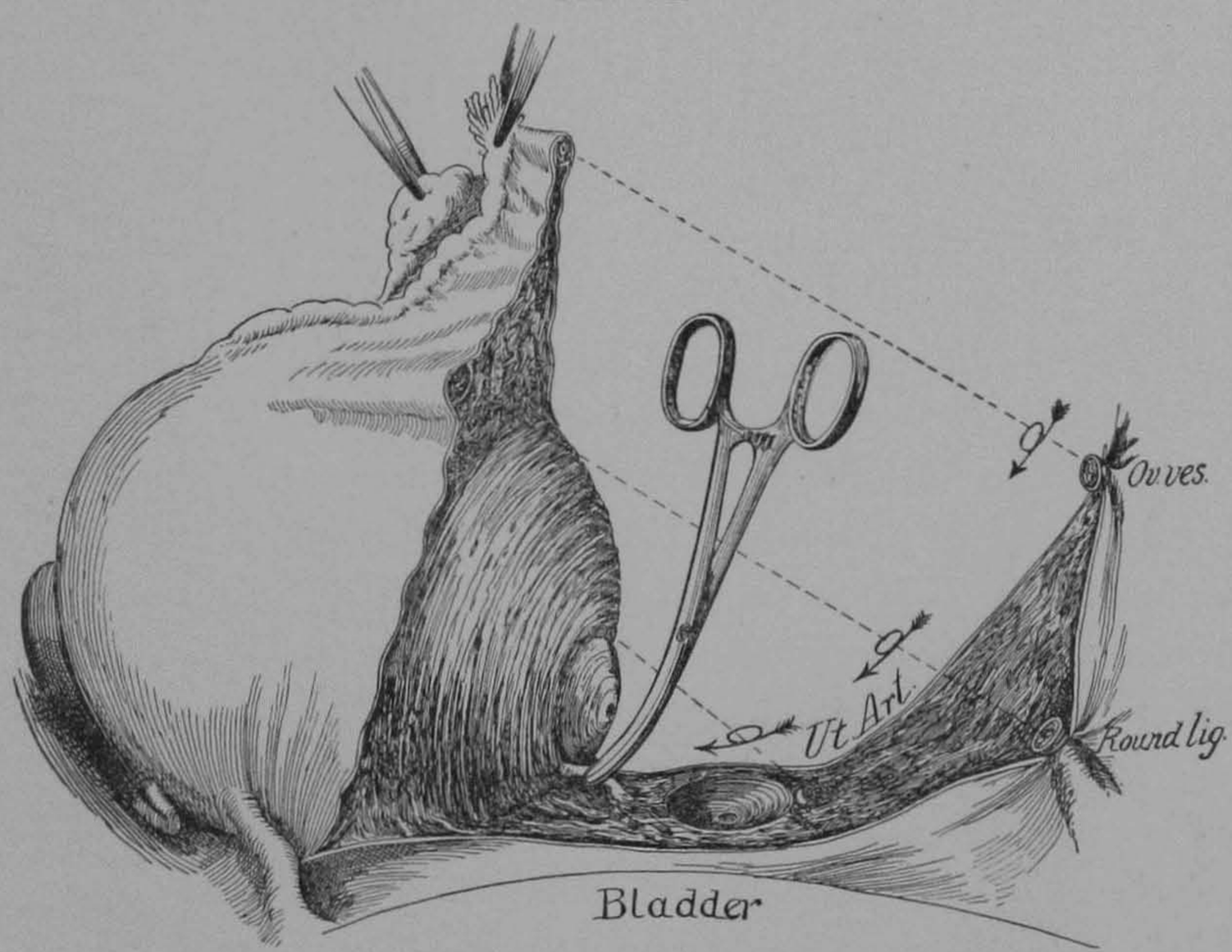

Left ovarian vessels tied, vesical peritoneum divided and pushed down, and left uterine vessels ligated. Cervix amputated and uterus pulled up and out, exposing right uterine artery, which is clamped an inch above the cervical stump. The two following steps are clamping the right round ligament and right ovarian vessels, when the mass is removed.

The operation (see Fig. 251) is begun as above by tying off the ovarian artery on the free side of the uterus, cutting through the broad ligament down to the uterine artery on the same side, and ligating it as before. The ligated uterine artery is now severed, and by drawing the uterus forcibly to the opposite side it is amputated at its neck. The bladder is freed from the uterus in the usual manner.

Immediately on amputating the uterus the opposite uterine artery comes into view and is grasped with a pair of forceps. This artery is at once severed, and by continued strong traction on the uterus the broad ligament on this side is torn through in an upward direction until the ovarian artery is reached. This artery, together with the round ligament, is caught with forceps, and the remainder of the broad ligament cut through. Ligatures at once replace the forceps, and the operation is completed as in the ordinary procedure. The danger in the operation lies in a failure to find the vessels and grasp them in forceps, and in severing the ureter. An expert will know how to avoid these dangers. The ordinary surgeon will succumb to them not infrequently. In intraligamentary neoplasms and in pelvic inflammatory conditions in which the adhesions are so universal as to make the line of division between the sigmoid and rectum and the diseased masses too uncertain to venture on breaking up the mass, or are so dense as to necessitate the use of too great force, this procedure will be found to render apparently hopeless cases comparatively easy.

There are three elements in the intra-abdominal amputation operation worthy of note: its bloodlessness without elastic temporary ligation, absence of raw surfaces from dissecting off the bladder, and avoidance of ligatures about the cervix, which tissue is free from the possibility of sloughing. It has all the advantages, then, and none of the drawbacks, which attach to all other methods of treating the pedicle intra-abdominally. We believe it to be the ideal operation of its kind. This procedure may be employed in any and every condition in which it is desirable to remove the uterus, except in the presence of malignancy or tuberculosis of the uterus.

When considering the intraperitoneal operation, and in view of the ease with which the vagina may be rendered sterile, the question naturally suggests itself, "Why not go a little farther and remove the cervix too?"

Total Abdominal Hysterectomy.—The patient is to be prepared as for both a vaginal hysterectomy and cœliotomy. Here, again, as many times before, stress is laid upon the importance of thoroughly cleansing the vagina and the difficulty in doing so by the usual methods. Trendelenberg's posture occupies to this operation what Sims's does to vesico-vaginal fistula: it renders the operation not only possible, but comparatively easy. But two instruments need be mentioned as supplementary to the ordinary ovariotomy set: blunt and sharp Deschamp's needles for ligating *en masse.*

PLATE XXI.

FIG. 3.

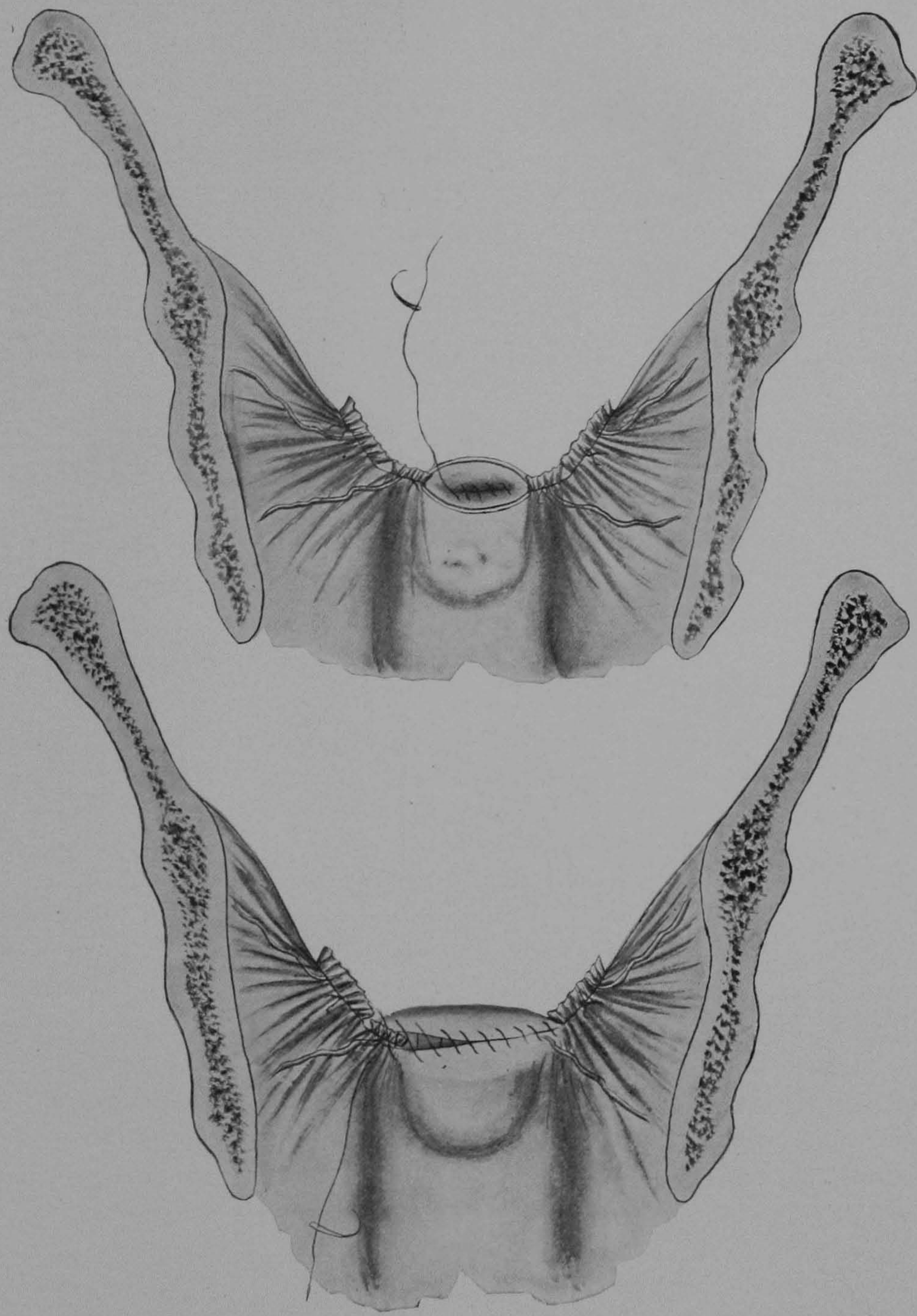

FIG. 4.

FIG. 3.—Supra-vaginal Amputation of the Uterus: cervical canal being closed by sutures which are buried by subsequent sutures.

FIG. 4.—Supra-vaginal Amputation of the Uterus: peritoneal edges of the stump in process of being whipped together, the lower stump being buried under the peritoneum.

Jamie L. Furrh, MSIS
Digital Projects Librarian
Gibson D. Lewis Health Science Library

UNIVERSITY *of* NORTH TEXAS
HEALTH SCIENCE CENTER
at Fort Worth
★
Education, Research,
Patient Care *and* Service

3500 Camp Bowie Boulevard
Fort Worth, Texas 76107-2699
817-735-2588 Fax 817-763-0325
800-687-5302
jamie.furrh@unthsc.edu
http://library.hsc.unt.edu
http://digitalcommons.hsc.unt.edu

The objective points are the two ovarian and two uterine arteries, for these furnish the main blood-supply of the uterus and tumor.

The operation which will be described may be applicable to all cases of fibroid tumor, intraligamentous as well as others, and to all other diseased states of the uterus and adnexa where it is desired to ablate the uterus together with the adnexa through the abdomen. The typical operation will first be described and then its modifications.

Fig. 252.

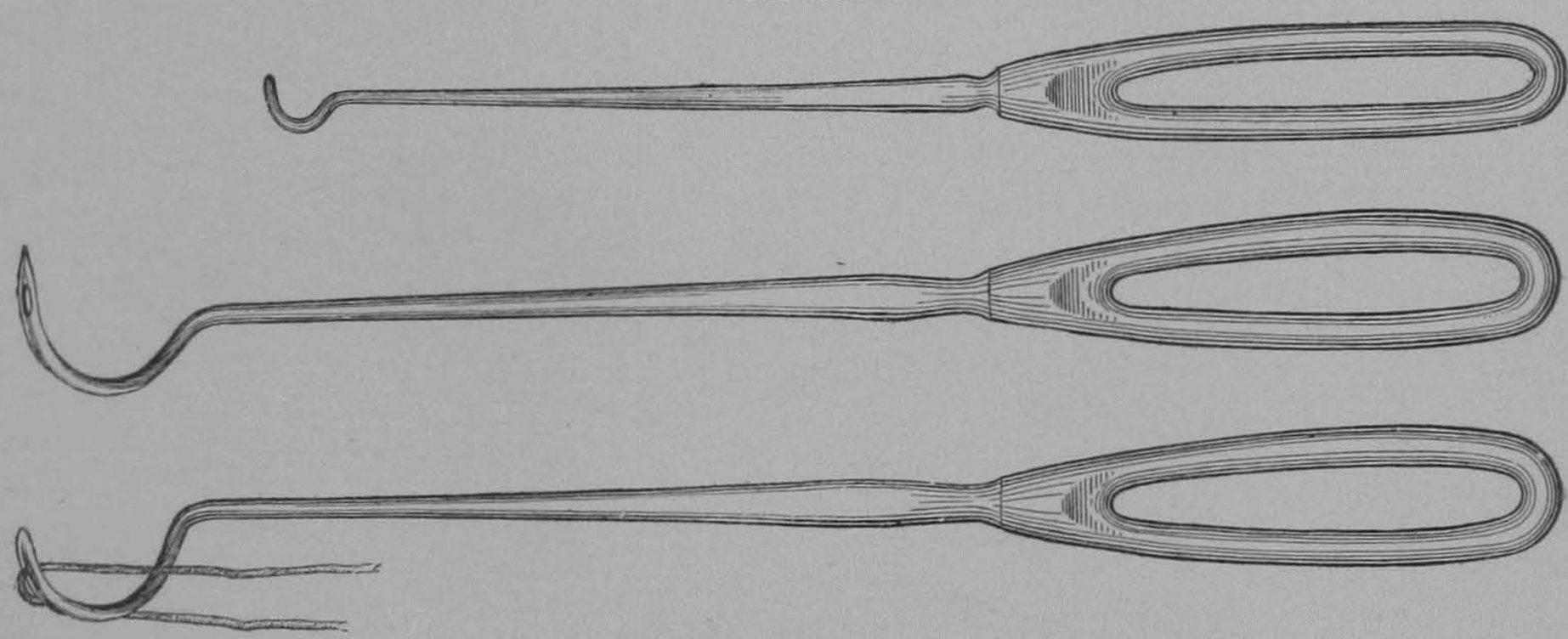

Deschamp's Needles.

Operation.—The uterus is curetted and irrigated, but not packed. If the cul-de-sac is readily accessible, it may be opened through the vagina and a wad of iodoform gauze inserted into the opening. The patient is placed upon a Trendelenberg table. While the assistants prepare the field of operation the operator disinfects himself again.

Upon entering the peritoneal cavity the patient is thrown into Trendelenberg's posture and the intestines forced into the abdomen, where they are held by large gauze pads. The pelvis being freed from intestines, the operator carefully inspects its contents, and close to the pelvic brim the ovarian arteries and veins are secured by single ligatures of fine silk. (See Plate XXIII.) A ligature is thrown around the ovarian vessels close to the cornua of the uterus. Near the first ligature and outside the ovary and fimbriated end of the tube the operator begins the section of the broad ligament. He cuts through the broad ligament close to the uterine-ovarian arterial anastomosis at the side of the uterus. The ovarian artery upon the other side has been similarly secured, and the broad ligament divided as described. This leaves both ovaries and tubes attached to the uterus. The operation up to this point is precisely similar to

the intra-abdominal supravaginal hysterectomy. The posterior cul-de-sac is now entered, or, if it has been opened at the time the uterus was curetted, the gauze plug is withdrawn and two fingers are inserted into the vagina through the cul-de-sac. The ends of the fingers are hooked beneath the cervix and make upward pressure against the anterior face of the cervix. The operator now begins the separation of the bladder from the uterus. In doing this the fingers in the vagina will be of material assistance in mapping out the relations of the parts. A crescentic incision is made

FIG. 253.

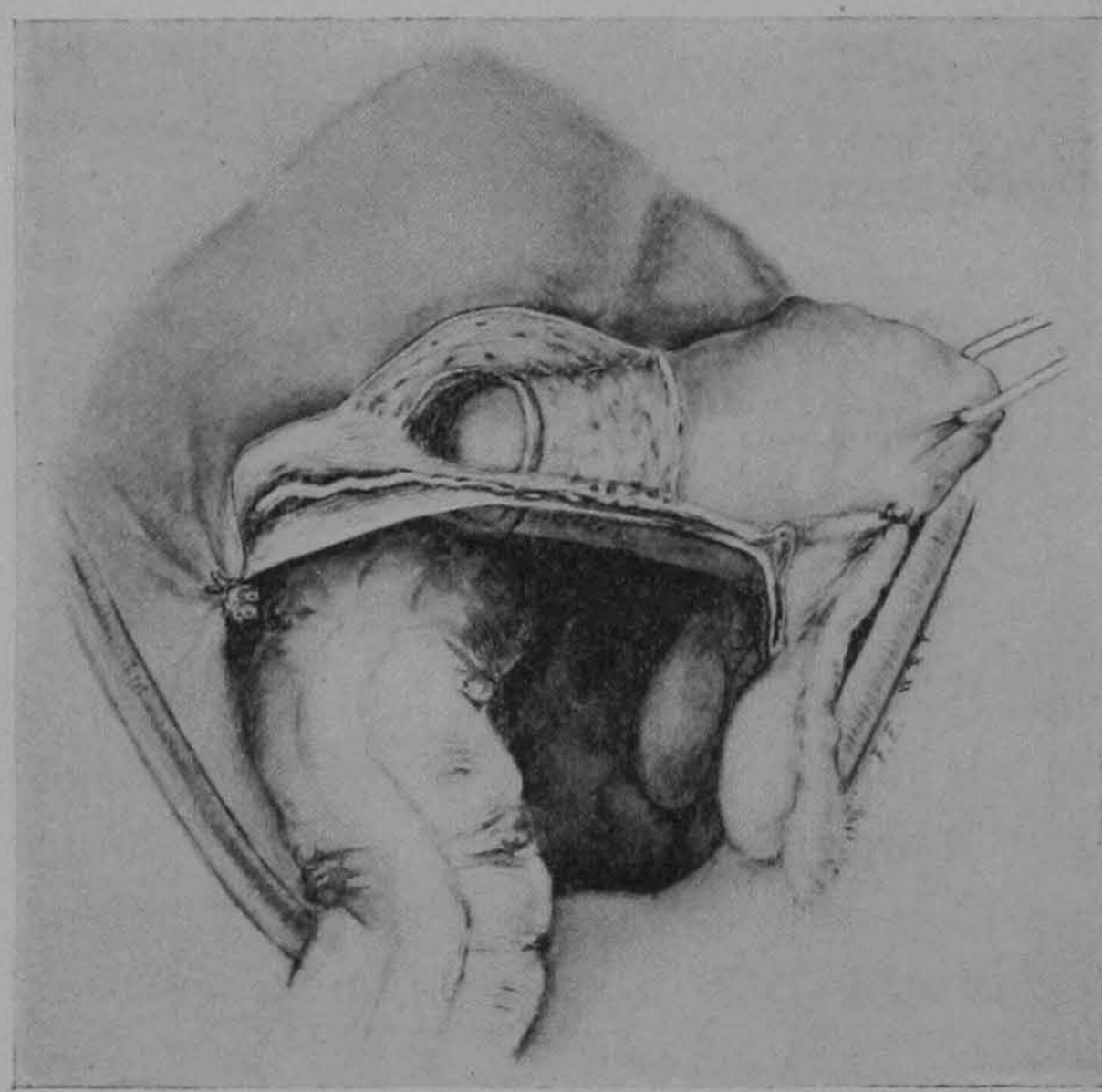

Both ovarian arteries are tied, but the ligature upon the left only is seen. The cul-de-sac is opened, and the bladder has been dissected away from the uterus. The broad ligament has been split to show the course of the uterine artery, which is seen to cross the ureter at its passage beneath the base of the broad ligament. The uterus is pulled to the right. (From a photograph of an operation.)

from side to side across the anterior face of the uterus just above the utero-vesical fold. Laterally this incision stops short of the sides of the uterus. Having severed the peritoneum and loose fascia beneath it down to the uterine tissue proper, the operator dissects the bladder away from the uterus with the ends of two fingers. In doing this he is careful to keep the points of his fingers pressed hard against the uterus, and in this way avoids wounding the bladder. After the vagina has been entered in front, the fingers are withdrawn from the vagina and the two indices are inserted into the posterior cul-de-sac, while the middle fingers are placed between the bladder and uterus. The hands are back to back, and, as the operator separates them by pushing outward, he pushes away from

PLATE XXII.

FIG. 1.

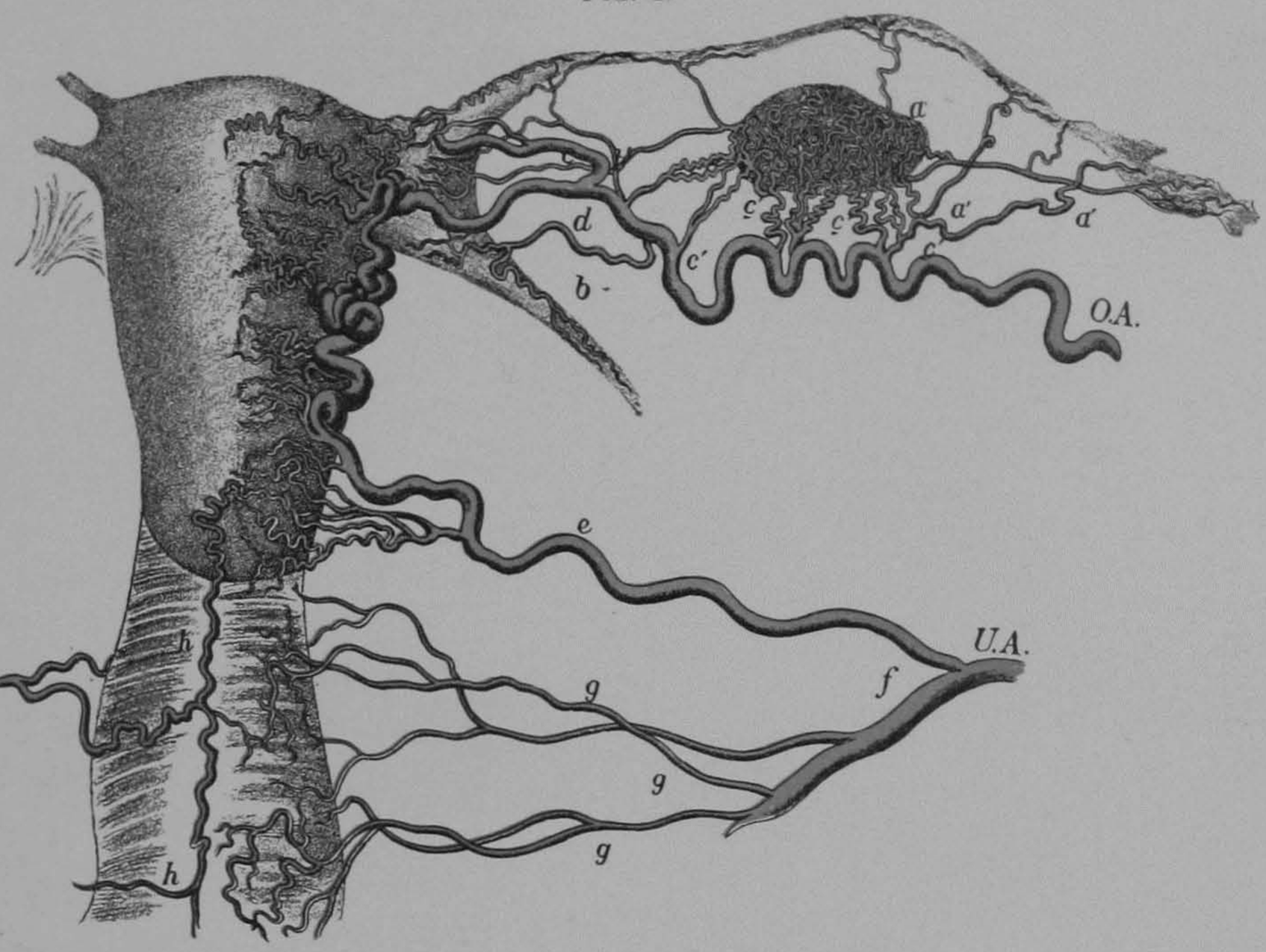

Arterial Blood-supply of the Uterus and Adnexa: *O. A.*, ovarian artery; *a'*, *a'*, *a'*, branches to ampulla of Fallopian tube; *c'*. *c'*. *c'*, branches to ovary; *c*, branch to fundus; *d*, branch anastomosing with uterine; *b*, branch to round ligament; *e*, uterine artery; *g*, *g*, *g*, vaginal arteries; *b*, *b*, azygos artery of vagina.

FIG. 2.

Venous Blood-supply of the Uterus: *b*, uterine artery; *c*, vaginal artery

FIG. 254.

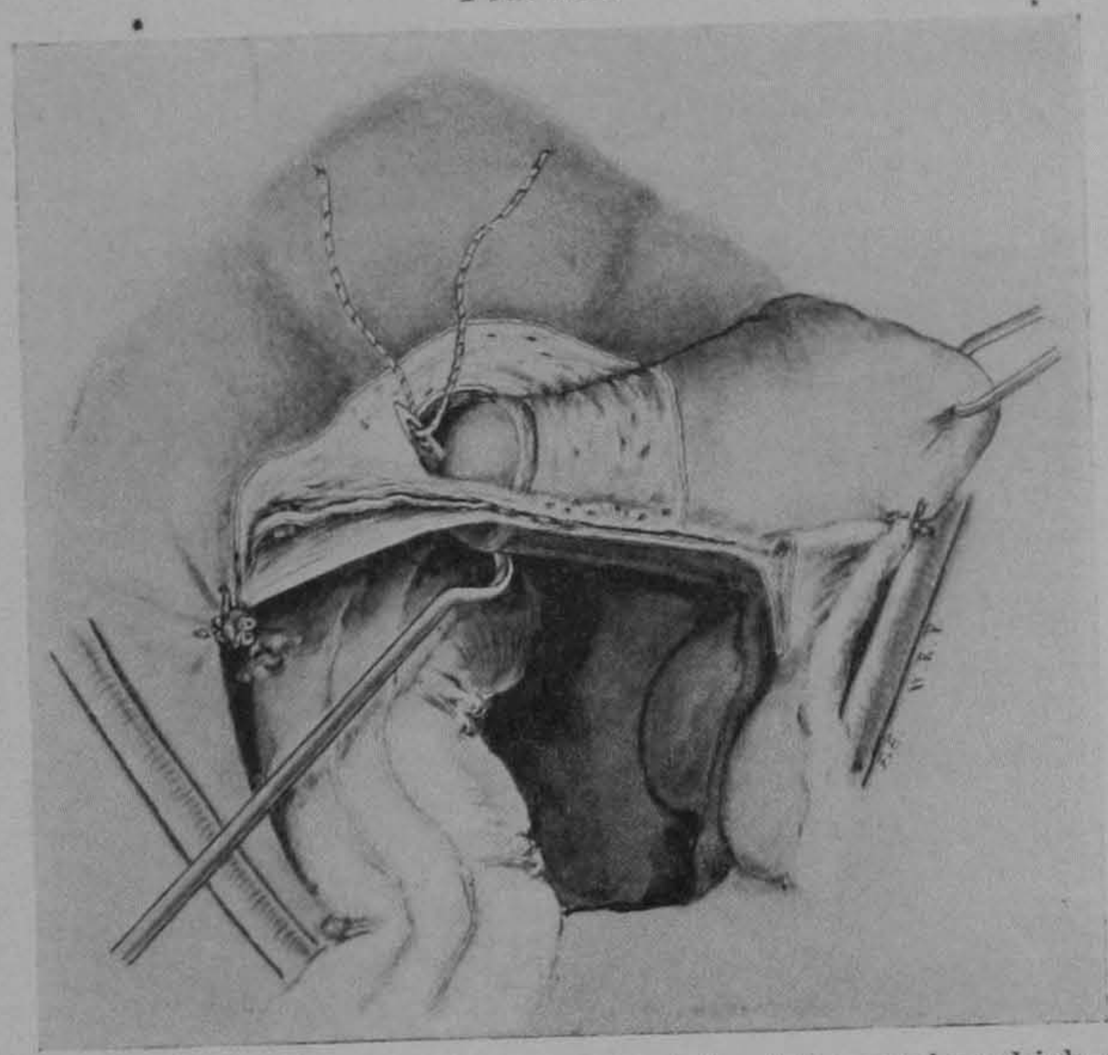

The Deschamp's needle circles the strip of tissue to the left of the cervix, which contains the uterine artery, by passing through the open cul-de-sac behind, across the vagina, to emerge from the open cervico-vesical space. The ureter is well shown at the outer end of the rent in the broad ligament. (From a photograph of an operation.)

the uterus all loose tissue upon each side, and this he does until he finds the uterus entirely free except at its lateral margins. He may

FIG. 255.

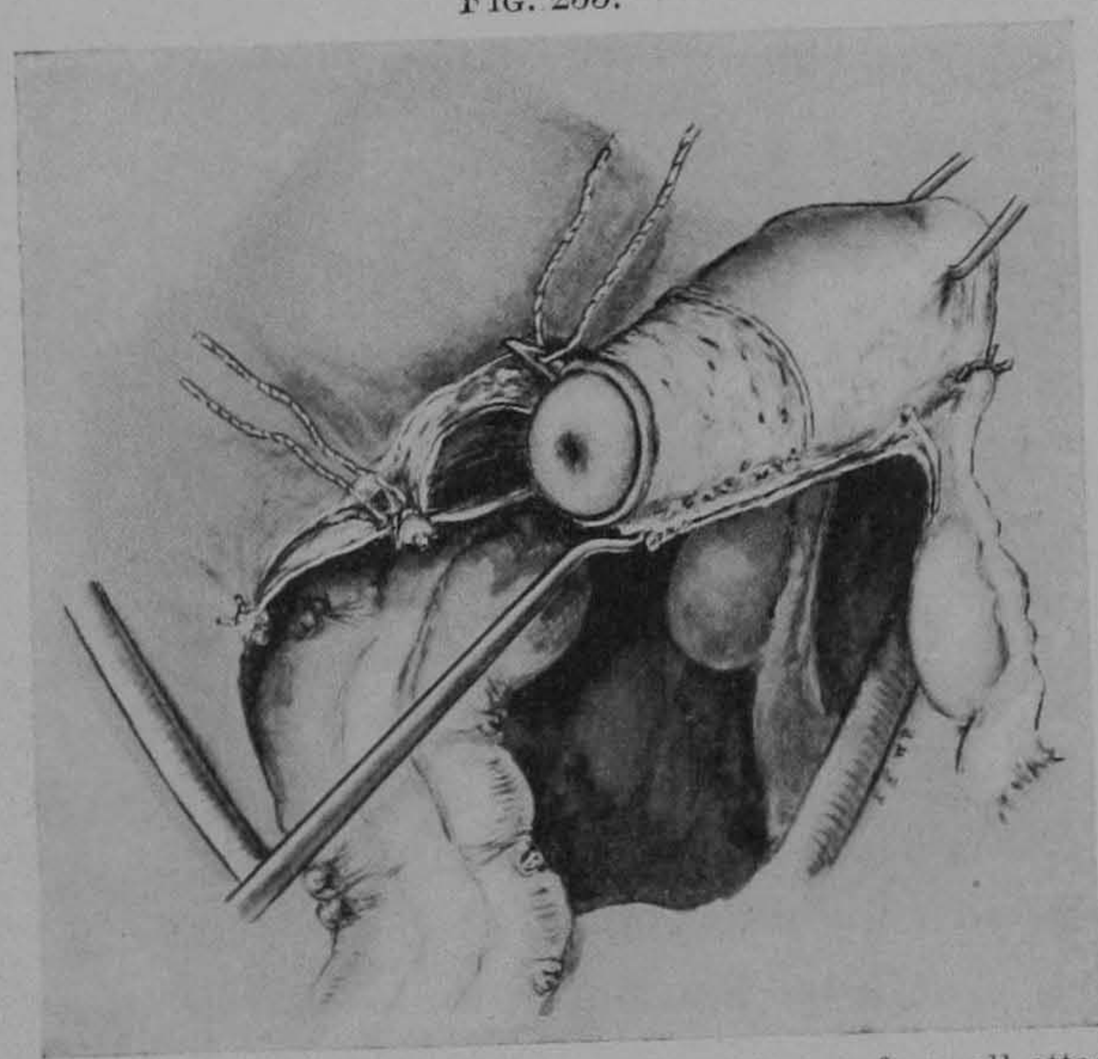

The left uterine artery has been tied *en masse* and the uterus cut away from all attachments on the left. The uterus is tilted far over to the right. The Deschamps needle is passing through the base of the right broad ligament to secure the right uterine artery. Both ovaries and tubes are seen. (From a photograph of an operation.)

now proceed in one or two ways: He may ligate the uterine artery either *en masse* or in continuity upon one side between the folds of the broad ligament and about half an inch from the cervix, then cut

away the cervix, and ligate the uterine artery in a similar manner upon the other side, and remove the uterus and adnexa; or, if he be cramped for space or is embarrassed by capillary bleeding, he may secure each lateral pedicle containing the uterine arteries with heavy forceps and remove the uterus, subsequently ligating the uterine vessels after the uterus and adnexa are out of the way. Much time will be saved if the operator secures the stump, holding the uterine arteries by ligatures applied to the tissues *en masse*, and without seeking to pick the uterine vessels out. In doing this he uses very heavy braided or twisted silk and ties it with great force, the loop circling all the tissue upon each side of the cervix. The

FIG. 256.

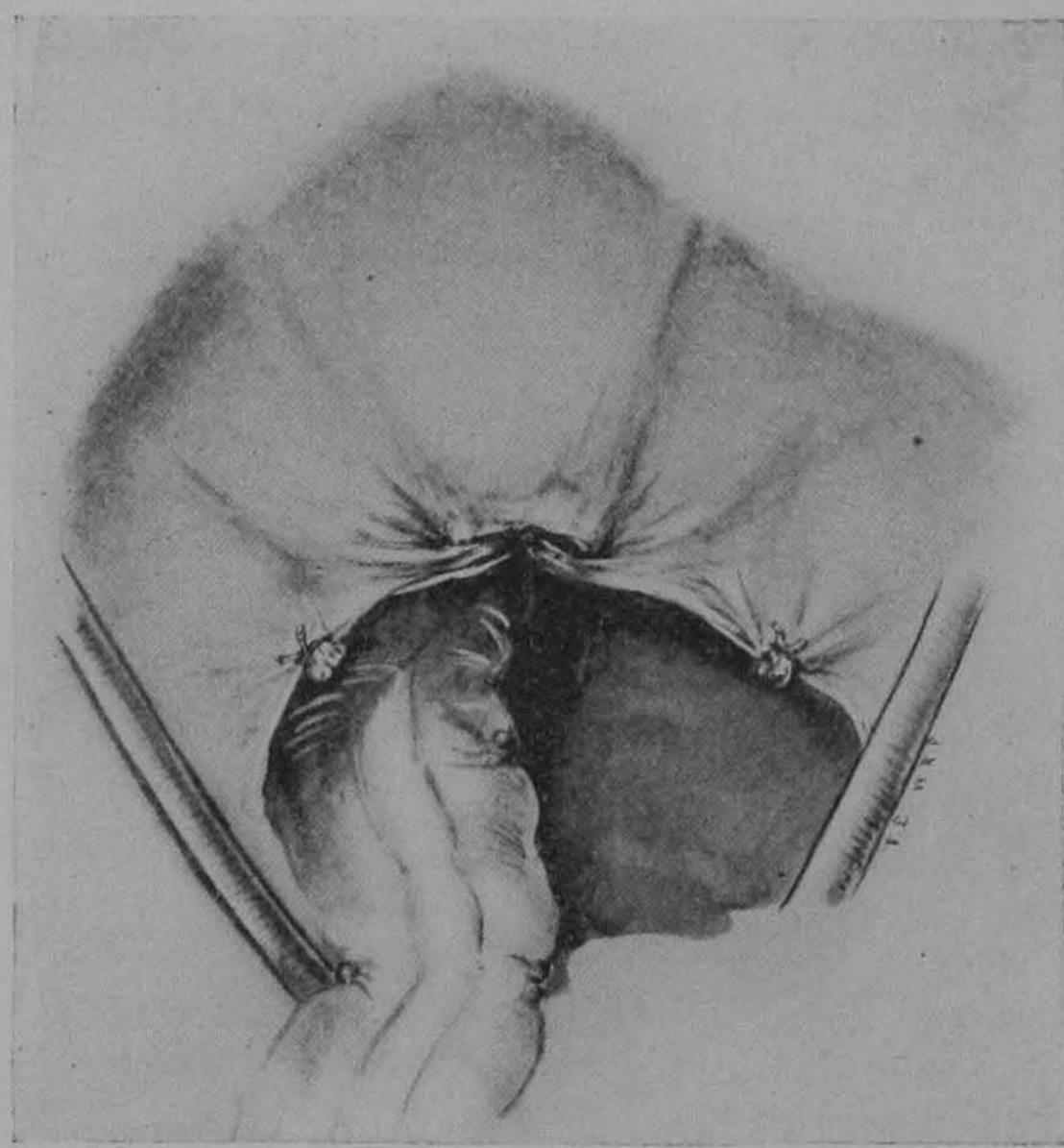

The completed operation. Both ovarian arteries are shown tied and the ligatures cut short. The stumps of the broad ligaments containing the uterine arteries are drawn down into the vagina. (From a photograph of an operation.)

ligatures on the ovarian vessels are cut short, while those upon the uterine arteries are left long and turned down into the vagina. The vagina is filled with iodoform gauze, the upper end of which, nicely smoothed over, protrudes but a fraction of an inch above the incision in the vagina. If the azygos artery on the posterior vaginal wall is large enough to spout, it is secured by catgut ligature and any bleeding points on the bladder wall are similarly tied. The pelvis is wiped dry and the patient lowered into the horizontal posture. It will now be seen that the bladder and rectum fall together, completely shutting from view the vaginal wound and stumps of the

PLATE XXIII.

Fig. 1.

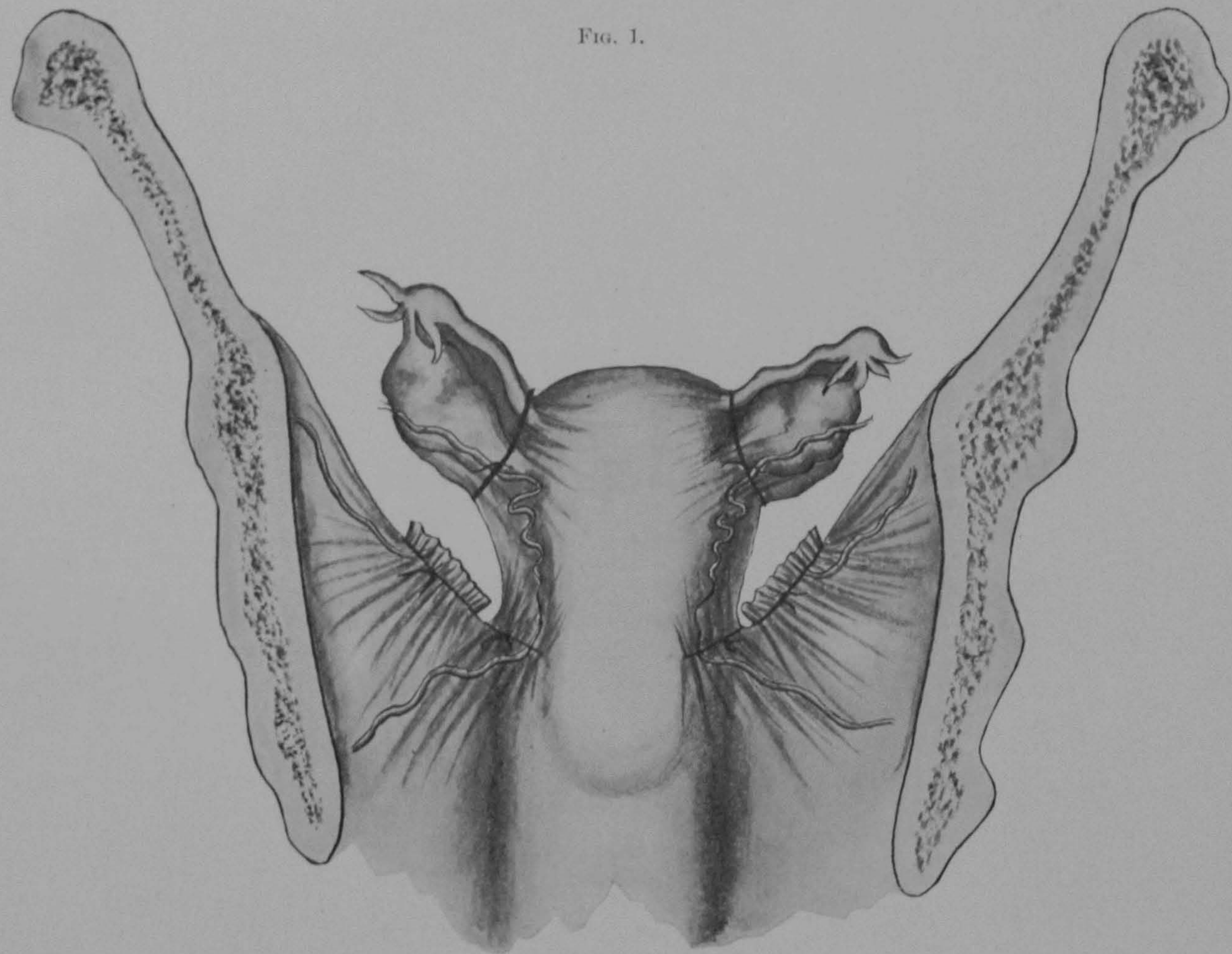

Total Abdominal Hysterectomy : first step.

UNIVERSITY of NORTH TEXAS
HEALTH SCIENCE CENTER
at Fort Worth
★
Education, Research,
Patient Care and Service

Jamie L. Furrh, MSIS
Digital Projects Librarian
Gibson D. Lewis Health Science Library

3500 Camp Bowie Boulevard
Fort Worth, Texas 76107-2699
817-735-2588 Fax 817-763-0325
800-687-5302
jamie.furrh@unthsc.edu
http://library.hsc.unt.edu
http://digitalcomm.

uterine arteries. The gauze pads are removed from the abdomen and the abdominal incision is closed (see Technique). Instead of drawing the uterine artery stump into the vagina and packing with gauze, the edge of the vaginal mucous membrane may be whipped together by a continuous catgut suture, and over this the edges of the peritoneum may be similarly united, burying the stumps of the artery between the vagina and peritoneum. By this procedure subsequent attention to the wound is dispensed with. The ligatures on the arteries have of course been cut short. (See Plate XXV.) The urine is drawn and the patient put to bed. On the eighth day, if the temperature has been normal, the patient is placed in the lithotomy posture and the vaginal dressing changed. The ligatures on the uterine arteries, if they have been left long and turned into the vagina, may be cut after this at any time or may be allowed to come away later. Traction upon them is not to be made. The mass of lymph which forms about the vault of the vagina implicates the bases of the broad ligaments which contain the stumps of the uterine arteries, and the resultant scar holds the vault of the vagina high up.

Where very large fibroids are to be dealt with, it is advisable to eventrate the tumor before securing the vessels or attempting the ablation. In certain of these cases the tumor may be constricted by a stout elastic ligature applied above the cervix and the great mass of tissue removed. This procedure is particularly applicable where the larger tumor of a nest of growths is pedunculated.

The operation for *intraligamentous fibroids*, proposed by Pryor, proceeds as described up to the point of securing the ovarian arteries. This artery is secured upon the *free side* only at this time. After this is done the operator dissects away the bladder from in front and ligates the uterine artery upon the *free side.* He now cuts the uterus away upon this side, opening the vagina as freely as possible. In order to secure the uterine artery upon the side of the intraligamentous nodule, he has an assistant tilt the uterus far over to the side of the nodule, so as to expose the interior of the vagina. The sharp Deschamps needle, threaded with stout silk, is passed close to the cervix up to the sulcus between the cervix and intraligamentous growth. The needle is forced around the uterine artery and emerges into the vagina again. It is tied and the cervix cut loose. It is now a very easy matter to peel the nodule out of the broad ligament without causing hemorrhage, and, when once freed, the uterus is held by

the folds of the capsule of the nodule. A few strokes of the scissors applied upon the anterior and posterior faces of the uterus close to its side will take the uterus and tumor away. If the Fallopian tube be spread over the capsule, its removal is not attempted, but the ovarian artery on this side is tied close to the cornu. The operator seeks to avoid splitting the capsule of the nodule, for in doing this he severs large venous sinuses and runs the risk of cutting a possibly misplaced ureter. The venous sinuses must be ligated if cut, and this conduces to the formation of sometimes enormous hematoceles beneath the peritoneum. Sometimes the tumor, as it grows out into the broad ligament, pushes the uterine and ovarian anastomosis outward. In such a case the uterine artery will still be secured by the Deschamps needle applied to the sulcus between the tumor and cervix. Although the uterine artery is always at the sulcus mentioned, its anastomosis with the ovarian artery and its branches to the cervix may be displaced outward by the intraligamentous nodule. But these branches are rendered dry by the ligation of the ovarian artery above and of the uterine below. Hence they cause no bleeding when the nodule is pulled out. The operator, not being positive of his anatomical relations, must adopt the only safe method of enucleating the fibroid and removing it with the uterus. So long as he avoids incisions into its capsule and injury to the periphery of the capsule, he will not wound the ureter and will develop no bleeding of moment. Heretofore it has been the custom to split the capsule of the tumor above and shell out the nodule from between the severed folds of the broad ligament. In doing this there is much time lost, a good deal of hemorrhage developed from the large sinuses that cover these nodules, and very often has the ureter been wounded. This latter structure may lie beneath the nodule, over it, in front of it, or even posteriorly. We never know just where to find it, and there is always great risk of wounding it. There is, however, one spot in which it is never found, and that is directly against the cervix in the sulcus formed by the junction of the tumor and the uterus. The position of the uterine artery to these growths is constant. It lies beneath the tumor, and is always secured by the ligature applied as described. The capsule of the fibroid nodule collapses after the uterus is removed and requires no attention. The abdominal pressure causes it to remain closed, and drainage from its cavity is carried away by the vaginal dressing.

PLATE XXIV.

FIG. 2.

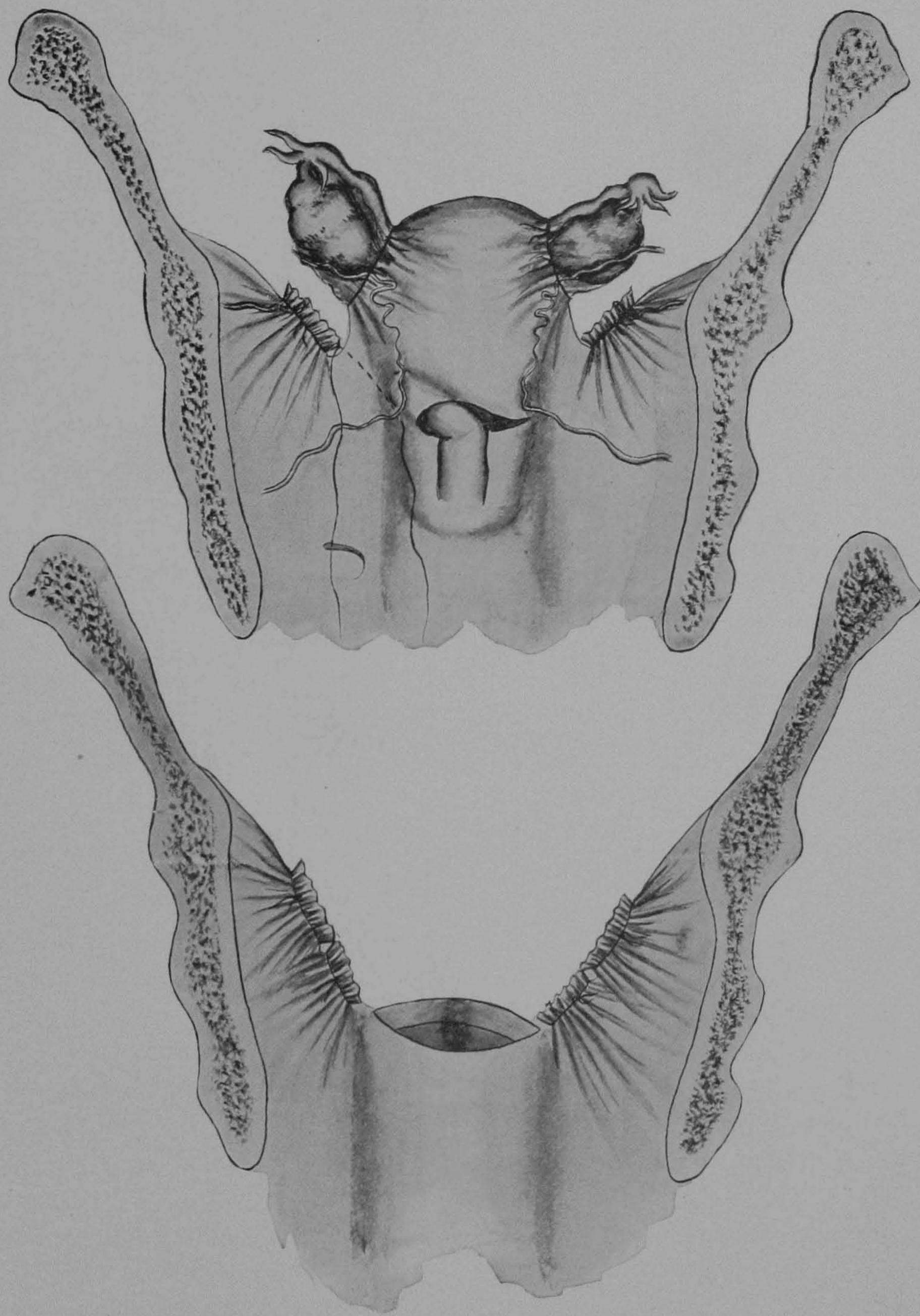

FIG. 3.

FIG. 2.—Total Abdominal Hysterectomy: second step. Vagina opened anteriorly, with the index finger in the vagina, while the ligature is being placed about the uterine artery.

FIG. 3.—Total Abdominal Hysterectomy: ovarian and uterine arteries ligated and uterus removed, leaving the vaginal vault opened.

Jamie L. Furrh, MSIS
Digital Projects Librarian
Gibson D. Lewis Health Science Library

UNIVERSITY of NORTH TEXAS
HEALTH SCIENCE CENTER
at Fort Worth

Education, Research,
Patient Care *and* Service

3500 Camp Bowie Boulevard
Fort Worth, Texas 76107-2699
817-735-2588 Fax 817-763-0325
800-687-5302
jamie.furrh@unthsc.edu
http://library.hsc.unt.edu
http://digitalcommons.hsc.unt.edu

Fibroids dissecting into the broad ligament, posteriorly beneath the peritoneal folds of Douglas's cul-de-sac, anteriorly into the bladder, or laterally toward the pelvic walls, are the most formidable growths the surgeon meets. They are not amenable to the tardy benefits to be derived from medicinal treatment or the operation of salpingo-oöphorectomy.

Fig. 257.

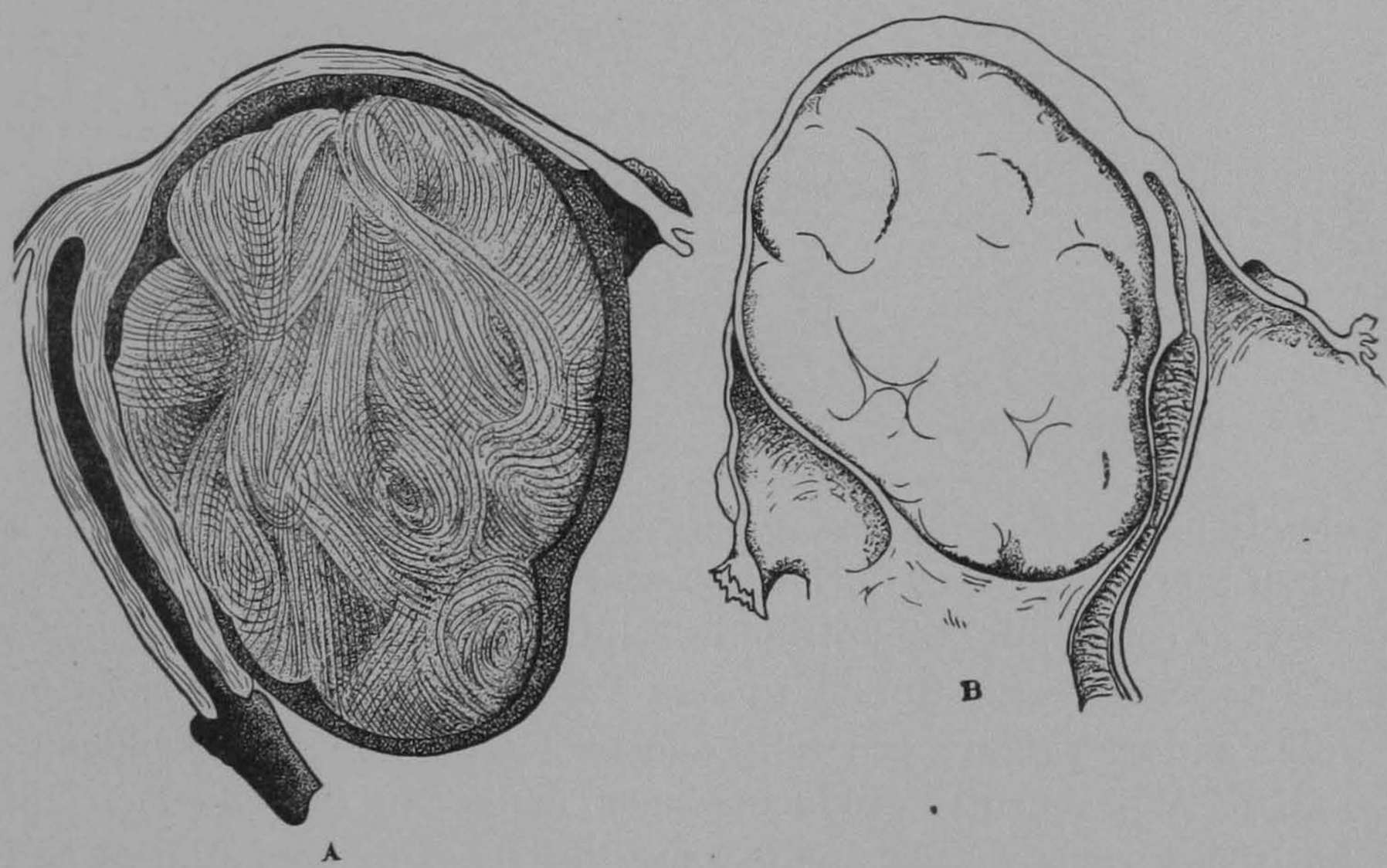

Intraligamentous Fibroma: *A*, abdominal variety; *B*, pelvic variety.

They can be removed by but two procedures: either by total extirpation or by the intra-abdominal amputation method, as already described.

Complications met during the Operation.—Adhesions may be entirely absent with the largest tumors, and, conversely, small tumors may present the most firm adhesions to important structures. They may attach the growth to any of the pelvic and abdominal contents, and are invariably of inflammatory origin. The adhesions are of two kinds, occurring as longer or shorter bands or as a close union between broadly adjacent surfaces. Bands are sparsely supplied with blood, but unions by broad attachment are very vascular. It occasionally happens that the fibroid will derive its main blood-supply from an adventitious adhesion. This is especially the case where subserous fibroids are attached to the omentum.

Band-like adhesions not very vascular may be torn with the

fingers or by scissors. Those which are vascular must be cut between two ligatures. Separation of the adhesions when broad must be made at the expense of the tumor, and not of the tissue to which it grows. This is pre-eminently the rule when the tumor is

Fig. 258.

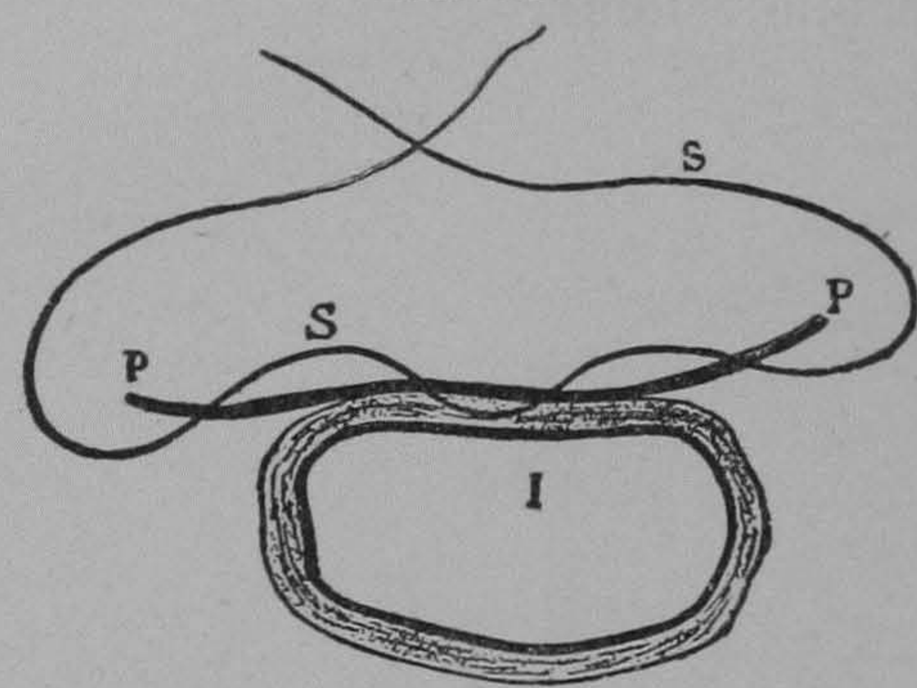

Suture of the Thin Fold of Peritoneum and Fibrous Tissue left after the Detachment of a Firm Adhesion from the intestine: *I*, intestine; *P*, peritoneal fold covering the fibroid; *S*, suture.

closely adherent to the gut. Adhesions are most general and firm when there have been former attacks of peritonitis.

Very commonly hypertrophic salpingitis and chronic oöphoritis are associated with fibroid tumors. But inflammatory lesions of tubes and ovaries are generally due to a septic or specific endometritis. As frequently producing such changes in the endometrium are the various means applied for the relief of hemorrhage and attempts at reduction of the tumor. Such are filthy curettements and injections of astringents. In other words, here more than in the uterus, not the seat of neoplasm, do we find improper intra-uterine manipulations one of the causes of complications in the adnexa or peritoneum. Milder degrees of tubal inflammation may result in occlusion only, thus producing hydrosalpinx.

It must not be forgotten that fibroid may exist coincidently with ovarian cystoma. Pus-tubes or ovaries should, if possible, be removed before the extirpation is begun, and the greatest care must be exercised not to permit the escape of any pus to soil the pelvic cavity. But cases do occur where the extirpation must first be made, the pus-focus being tied off from the tumor and enucleated as a last step.

In such cases the gauze packing must extend to the denuded surface produced by the removal of the pus-focus.

General Considerations.—The treatment to be selected for each case must not be determined by the character of the tumor

PLATE XXV.

FIG. 4.

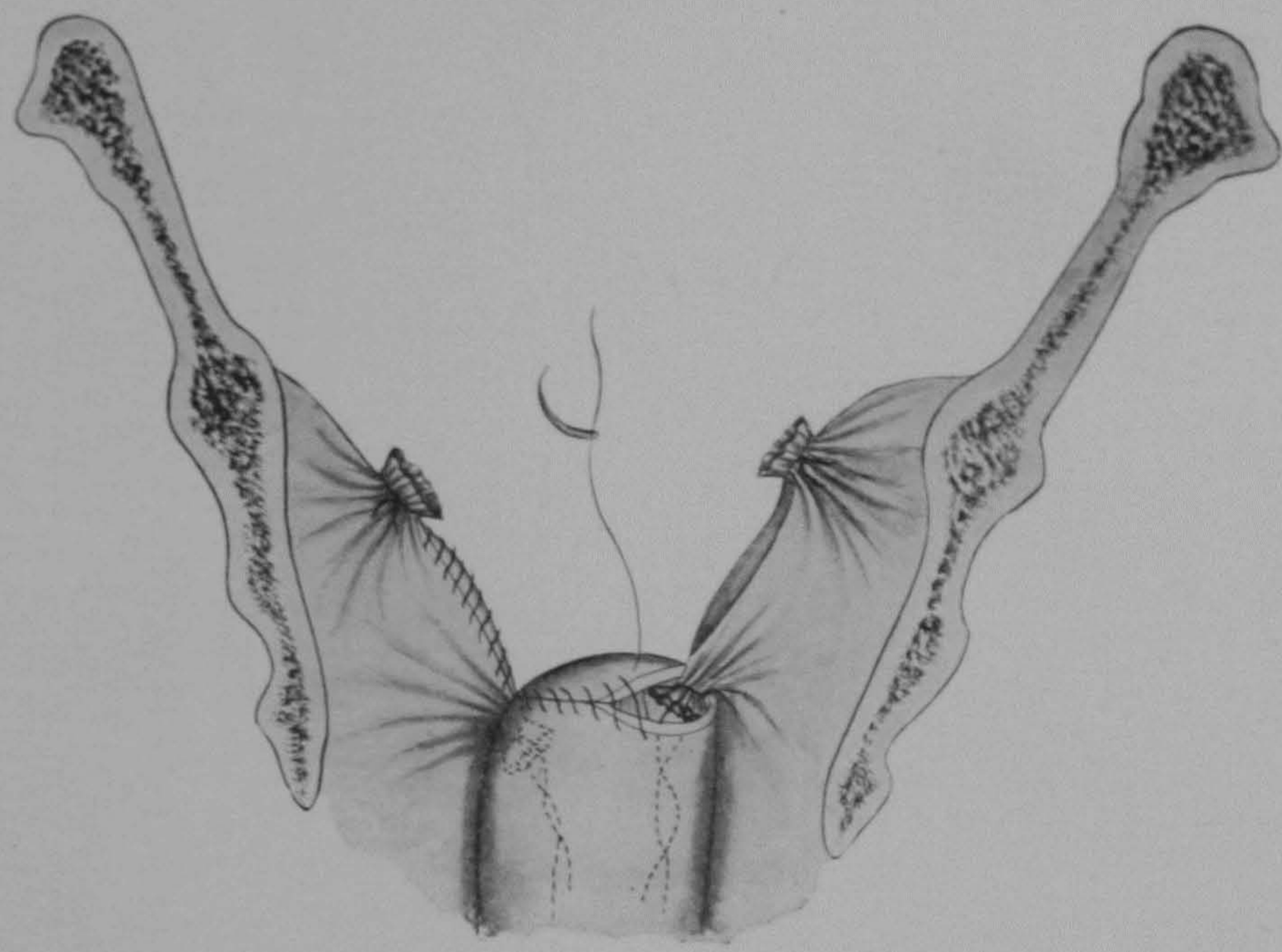

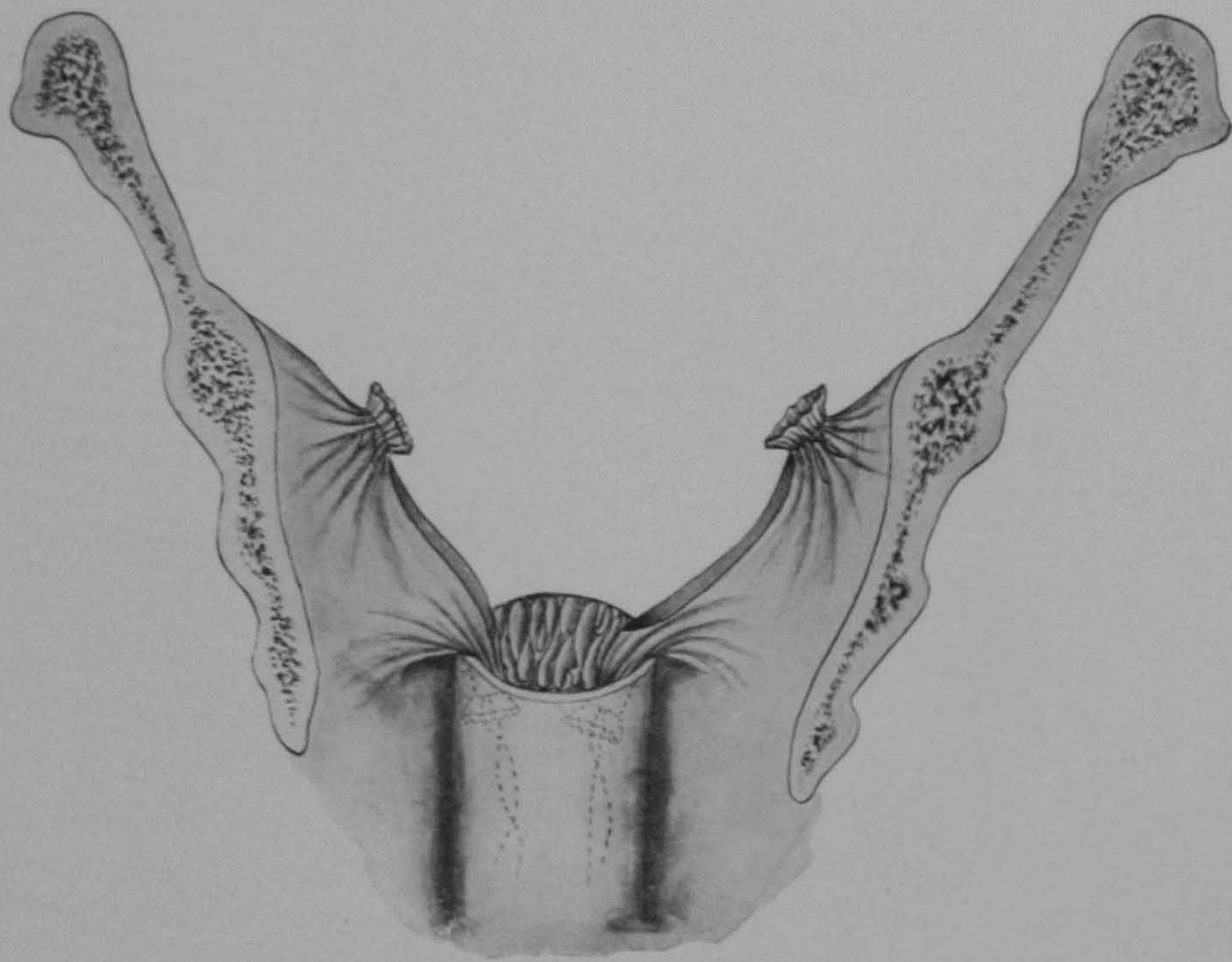

FIG. 5.

FIG. 4.—Total Abdominal Hysterectomy: vaginal vault in process of closure, with lower stumps drawn into the vagina. Opening in the left broad ligament closed.

FIG. 5.—Total Abdominal Hysterectomy: stump drawn into the vagina, and vaginal opening packed with gauze.

Jamie L. Furrh, MSIS
Digital Projects Librarian
Gibson D. Lewis Health Science Library

UNIVERSITY *of* NORTH TEXAS
HEALTH SCIENCE CENTER
at Fort Worth
★
Education, Research,
Patient Care *and* Service

3500 Camp Bowie Boulevard
Fort Worth, Texas 76107-2699
817-735-2588 Fax 817-763-0325
800-687-5302
jamie.furrh@unthsc.edu
http://library.hsc.unt.edu
http://digitalcommons.hsc.unt.edu

alone. Other considerations are to be entertained before arriving at the final conclusion. A patient who is in easy circumstances, who can afford idleness, and can secure comforts may well spare a few months of her life devoted solely to the effort of getting well by palliative and mild methods. The poor woman, a burden to her friends and unable even to secure necessary physical rest, will demand a measure which is radical. The general physical condition of a patient will determine the character of the operation more than any other one thing. An exsanguinated woman who is in good flesh will usually stand a long operation very well. Prolonged narcosis is dangerous if there be kidney or heart disease. Therefore it may be that many of the radical procedures would waste valuable time, and the most rapid method must be employed, even though it be incomplete. In skilful hands it does not take longer to extirpate the entire uterus than to properly attend to the stump by the various other methods. Some of the other methods have limitations, and there are certain tumors not amenable to each operation. Suprapubic extra-peritoneal amputation is not to be applied to virgins who have very short vaginæ, to fibroids which dissect into the broad ligaments, to those which burrow into the floor of the pelvis, and to those which already are septic.

Hegar's or Tait's operation of removal of the adnexa to induce artificial menopause and cut off part of the blood-supply has produced results which command our most careful attention. That it will check the growth of some tumors, and often cause them ultimately to disappear, is undoubted. But it is not immediate in its effect on the size of the growth, though the hemorrhages may cease at once. Therefore those tumors which have dangerous or very painful pressure effects demand a more radical procedure. It is hard to say just when the operation should be applied to the exclusion of all others, for tumors which respond most readily to this treatment also give the best results from a radical operation. Certain interstitial and subserous tumors require the greatest skill in their removal. In certain rare cases of intraligamentous growths, and in patients who will not bear a radical operation, we would suggest the salpingo-oöphoreetomy. Tumors of the soft, œdematous, fibro-cystic variety are but little, if at all, influenced by this operation. It is, then, limited to cases of hard myo-fibromata, and chiefly to those in women under thirty-five. It must undoubtedly be considered an incomplete operation with a limited application, for the natural meno-

stimulus to menstruation. But the perverted and pathological function has usually gone too far to be controlled by such mild means. There are very many cases in which the operation is so difficult as to be practically impossible. It can only be recommended in an extremely limited number of picked cases.

In his last work Tait quotes 262 cases with 4 deaths—1.5 per cent. mortality, about that incident to the electrical treatment, with vastly less suffering, much better results, and less injury to the woman in case the operation fails and a radical one becomes necessary. But these figures are for uncomplicated cases of fibromyoma.

We would, then, summarize the treatment of fibroids about as follows: Small fibroids which can readily be removed *per vaginam* may be subjected to that method. All others demand different procedures.

The patient's general condition and the character of the tumor would determine whether or not to operate. Cases in which the decision is against operation should be treated by ergot and ammonia.

An operation deemed advisable, total extirpation is indicated. The intra-abdominal amputation method is equally as good, it being in all essential respects a total extirpation, provided there is absolutely no possibility of malignant or tubercular disease being present. This operation has the advantage of being less dangerous than that of total extirpation.

The intra-abdominal methods of Zweifel and Schroeder are no longer necessary. The great leap has been from the extra-peritoneal operation to the intra-abdominal methods; and at the same time we leave a partial operation with a tedious convalescence, adhesions about the stump, and possibly hernia, for a complete operation, with a mortality less than 5 per cent. in the worst kind of cases, and no disagreeable sequelæ. In *selected* cases which have escaped electricity and other intra-uterine treatment the mortality should not be more than 3 per cent.

PLATE XXVI.

Intraligamentous Fibroid Tumor of the Uterus with Hydrosalpinx, showing the portions of the tumor which were buried under the peritoneum in the connective tissue: front and back views.

The Broad Ligaments are two quadrangular folds of the peritoneum, one on either side, situated between the uterus and the pelvic wall, & forming a partition in the true pelvis between an anterior and a posterior pouch. The inner edge is attached to the side of the uterus, the outer edge to the wall of the pelvis in a line extending from a point midway between the sacro-iliac articulation and the ilio-pectineal eminence, downward and backward, between the great sacro-sciatic notch and the obturator foramen, to the level of the spine of the ischium. The upper edge is formed by the Fallopian tube inward, and the infundibulo-pelvic ligament outward. The lower edge is attached to the mass of connective tissue, lying to the side of the cervix and called Parametrium or Parametric Connective Tissue. The upper edge is free; the three other edges are continuous with the peritoneal covering of the uterus, the sides and the floor of the pelvis. It is composed of an anterior and a posterior layer; the anterior covers the round ligament; the posterior layer contains an opening, in which the base of the ovary is inserted. Between these two layers lie loose connective tissue, unstriped muscular fibres, blood-vessels, lymphatics and nerves. The muscular fibres are a continuation of the outer layer of the uterine muscular coat and form a platysma between the uterus, the ovaries, and the tubes, from